

# **CHILD AND ADOLESCENT DENTISTRY**

## **A Picture Guide**

**Dr. Chandra Herath**

**Professor Nandani Nagarathne**

**2016**



© **Dr. Chandra Herath**  
**Professor Nandani Nagarathne**

**First Edition June 2016**

**All Rights Reserved**

**ISBN 978-955-43211-0-6**

**Edited by :**

Primali Jayasooriya  
M.D. Nagarathne

**Published by:**

Dr. Chandra Herath,  
BDS, MS (Resto), FDSRCS(Paedo)  
Consultant Paedodontist,  
Head,  
Department of Community Dental Health,  
Faculty of Dental Sciences,  
University of Peradeniya,  
Peradeniya.

**Printed by:**

Sanduni Offset Printers (Pvt.) Ltd.  
No. 4/1, Sarasaviyana, Goodshed Road,  
Sarasaviyana,  
Peradeniya.  
081-2387777



# **CHILD AND ADOLESCENT DENTISTRY**

## **A Picture Guide**

### **Dr. Chandra Herath**

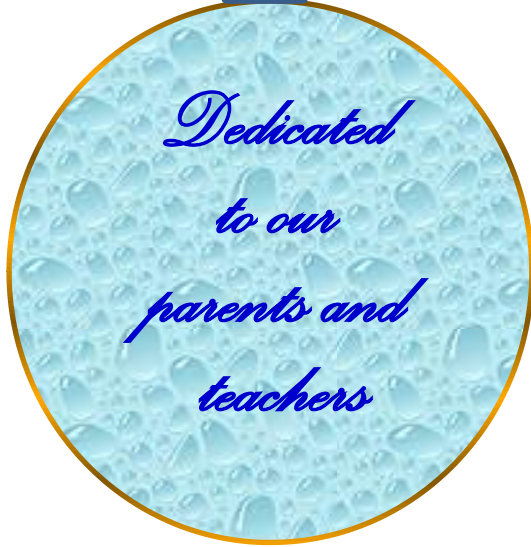BDS, MS (Resto), FDSRCS (Paedo)  
Senior Lecturer and Consultant Paedodontist  
Division of Paedodontics  
Department of Community Dental Health  
Faculty of Dental Sciences  
University of Peradeniya  
Peradeniya  
Sri Lanka

### **Professor Nandani Nagarathne**

BDS, MS (Ortho)  
Professor in Orthodontics  
Division of Orthodontics  
Department of Community Dental Health  
Faculty of Dental Sciences  
University of Peradeniya  
Peradeniya  
Sri Lanka

**2016**





*Dedicated  
to our  
parents and  
teachers*





## **ACKNOWLEDGEMENT**

I wish to acknowledge with sincere thanks Dr. Prabhleen Anand, Consultant Paedodontist, Eastman Dental Hospital, London, United Kingdom and Dr. Kumari Rathnathilake, Consultant Orthodontist, General Hospital, Kegalle who have read this picture guide and made their constructive suggestions to improve the content in their respective specialties. I also wish to acknowledge with great respect the invaluable contribution made by Professor Primali Jayasooriya, Faculty of Dental Sciences, University of Peradeniya and Dr. M.D. Nagarathne, Consultant Obstetrician and Gynecologist, Faculty of Medicine, University of Peradeniya, by editing this collection of cases with questions and Answers which made this picture guide a reality .

Further, I wish to thank Miss. Sanduni Weerathna who was instrumental in giving technical assistance for computer programming. I acknowledge all the staff members of the Division of Paedodontics and Orthodontics for their assistance to gather cases. I also thank all the staff of Sanduni Offset Printers for printing this book.

Finally, I am grateful to my husband Methsiri, daughters Thilini and Sanduni for the moral support given to me throughout the time I spent compiling this Picture Guide.



## FOREWORD

I am happy to write the foreword for the book titled “**Child and Adolescent Dentistry: A Picture Guide**” authored by Dr. Chandra Herath and Prof. Nandani Nagarathne. Teaching and learning methods, are changing with the advancement of information technology and other related facilities around the globe. It is a known fact that more and more self-learning materials are being added every day to student learning. This book is an attempt to facilitate the understanding of various oral diseases with the help of clinical pictures. It will not only improve the student’s diagnostic ability but also pave the way for self-assessment as Answers are also included.

The questions are formatted in such a way that the student can imagine the clinical scenario and try to find the Answers. This book provides a sound basis for undergraduate students to understand common oral diseases in children and adolescents. Authors had very appropriately used long years of experience in the respective fields to compile this picture guide. I am sure this book will be very useful to undergraduates as well as postgraduates to assess themselves on the subject of Child and Adolescent Dentistry.

Professor W.M. Tilakarathne,  
(BDS, MS, FDSRCS, FRCPath, PhD),  
Dean and Senior Professor of Oral Pathology,  
Faculty of Dental Sciences, University of Peradeniya,  
Peradeniya, Sri Lanka.



## INTRODUCTION

With the rapid advancement of sub specialization in Clinical Dentistry in the recent past, there has been a trend towards compartmentalization of the field into several disciplines.

But globally accepted concept at present is one health with contribution from several non-health related fields such as Agriculture, Veterinary Science, Water Resources, and Environment Management towards the betterment of mankind.

The aim of this Picture Guide is an attempt to familiarize the beginner in child and adolescent dentistry with this novel concept of one health.

This book includes a series of thought provoking questions with clinical pictures and Answers with additional explanation included where necessary.

Deliberate attempt has been made to include most of the clinical aspects in children and adolescent dentistry encountered in day to day practice with an emphasis on importance of maintenance of oral health care during pregnancy.

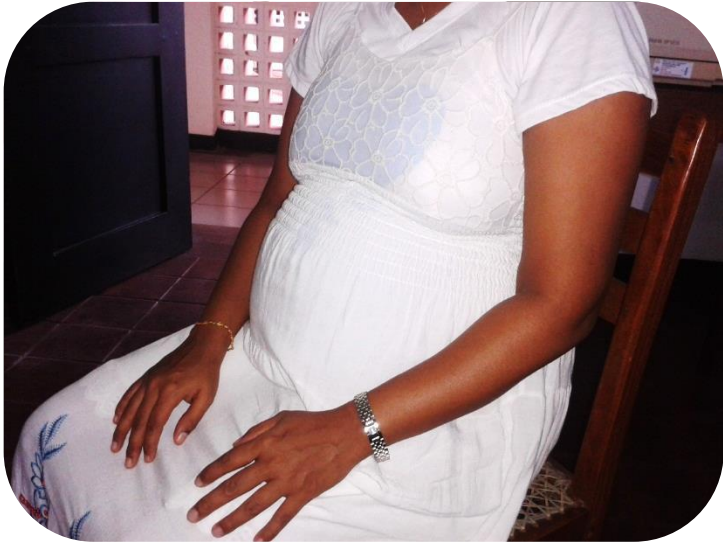

# Cases



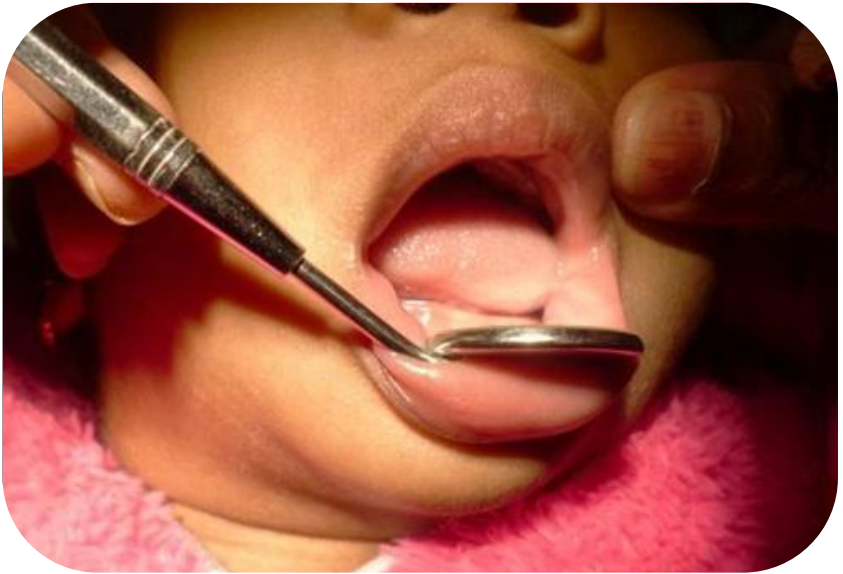


## Case 1



Why is it important to obtain regular dental treatment during pregnancy?

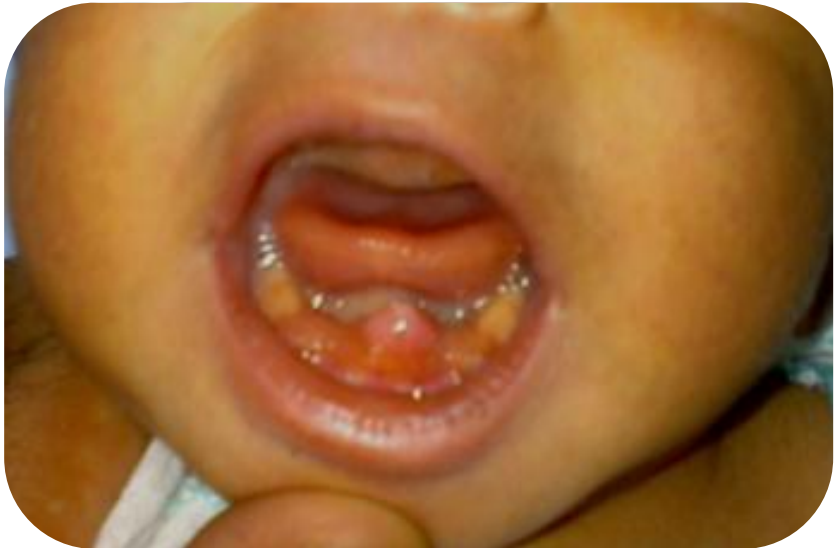## Case 2



A mother inquired about the oral care of her new born baby.

What advice would you give?

### Case 3

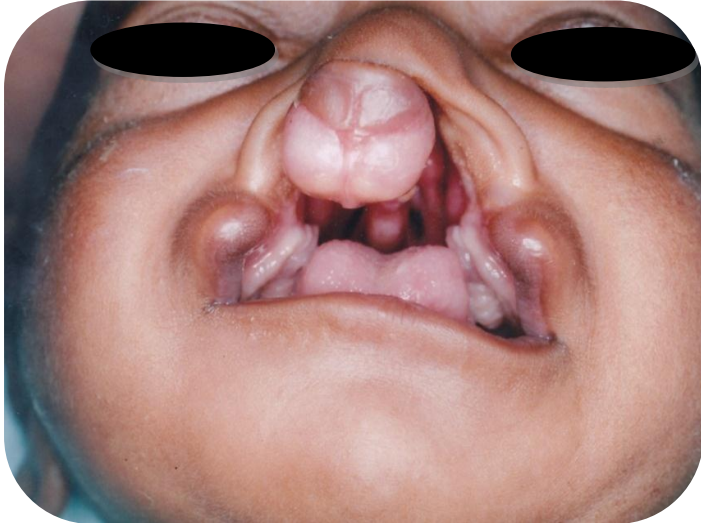

This new born baby was referred to the Paedodontic clinic with an abnormal growth in the lower gum pad.

3.1 What are your differential diagnoses?

3.2 How would you manage the conditions mentioned in 3.1?

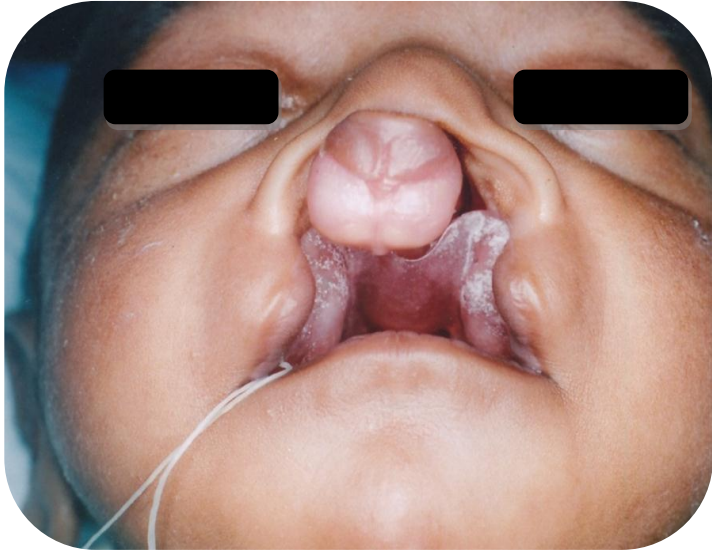
## Case 4



This is a photograph of a 2 week old baby who was referred for Orthodontic advice.

- 4.1 What is the abnormality seen?
- 4.2 What are the problems that the baby will have with this abnormality?

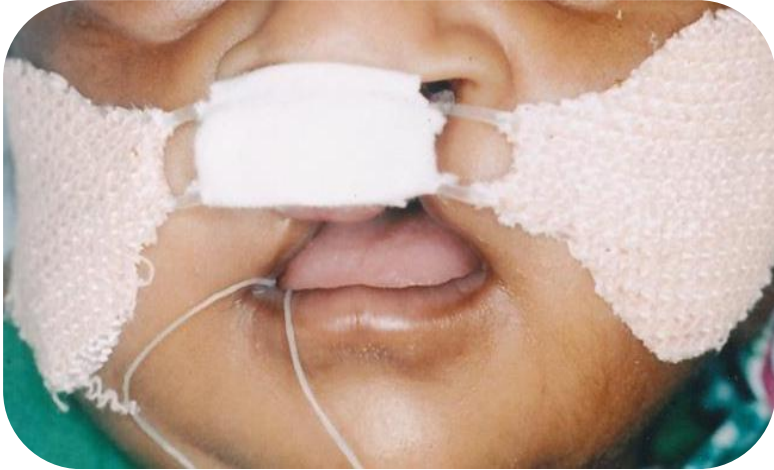## Case 5



The above appliance was fitted soon after the baby presented to the clinic.

- 5.1 Identify the appliance.
- 5.2 What is the advantage of this appliance to the baby and to the surgeon?

## Case 6

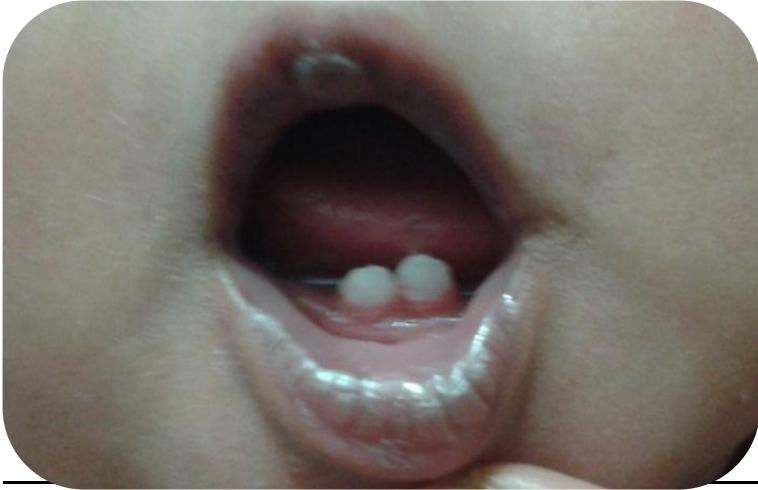

The same baby as seen in question number 5 was wearing the above extra oral device for three months in addition to the appliance fitted in the mouth.

6.1 What is the procedure that has been carried out?

6.2 What is the advantage of the procedure mentioned in 6.1?

## Case 7

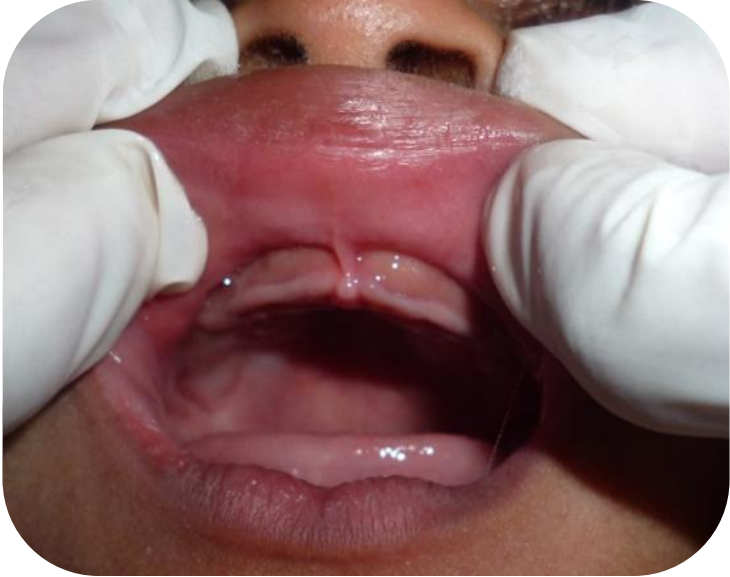

This 3 week old baby was brought to the dental clinic.

7.1 What is your diagnosis?

7.2 How would you manage the condition?

## Case 8



This 7 month old baby presented with a history of mild fever of one day duration and drooling of saliva for a few days.

- 8.1 Diagnose the condition.
- 8.2 List the clinical features that are associated with the condition mentioned in 8.1.
- 8.3 Outline your management.

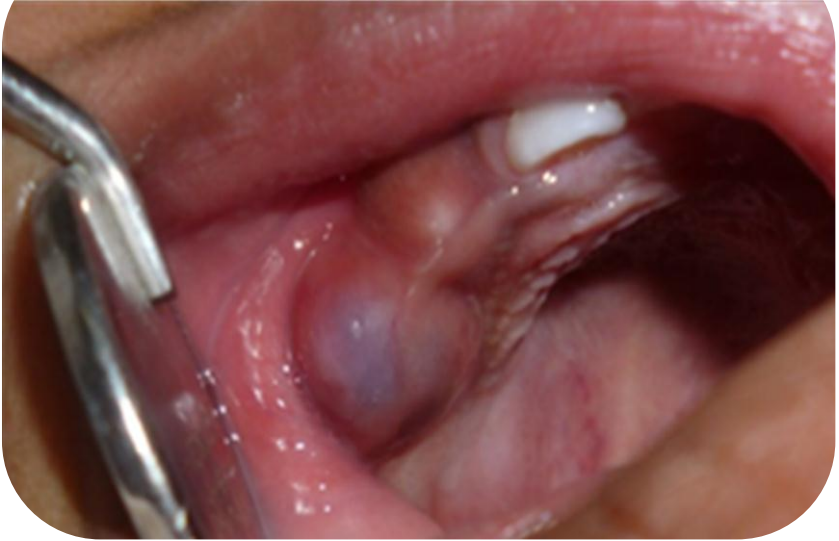

## Case 9



- 9.1 What advice would you give a mother regarding 'Finger Brush' which is commonly used in babies with one or two teeth?
- 9.2 Indicate the criteria for selection of a tooth brush for a growing child.

## Case 10

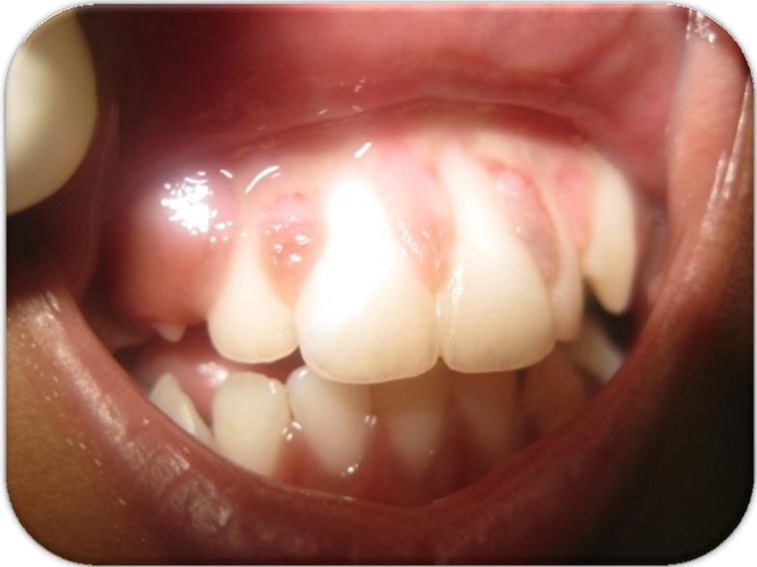

One year old child was brought to the clinic with a bluish swelling in relation to the right upper molar region.

10.1 What is your diagnosis?

10.2 How would you manage this condition?

## Case 11

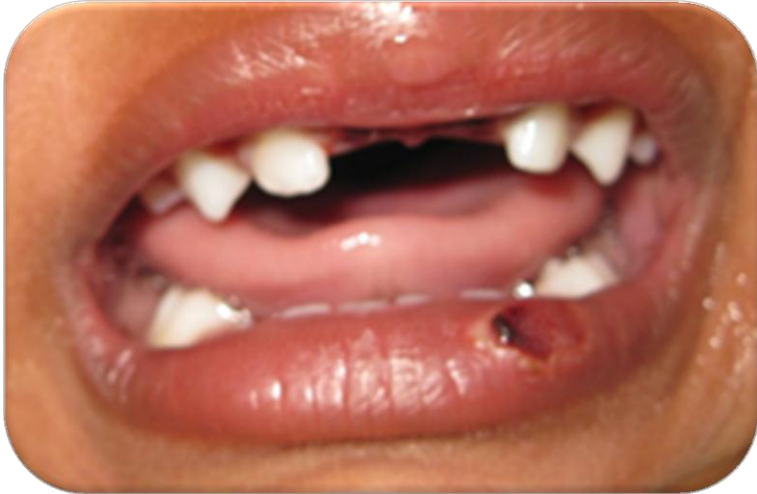

Parents of an 18 month old child received proper tooth brushing instructions for their child. Three months later they brought the child with a complaint of abnormalities in gingivae in relation to upper front teeth.

11.1 What could be the reason for this presentation?

11.2 How would you manage the condition?

## Case 12

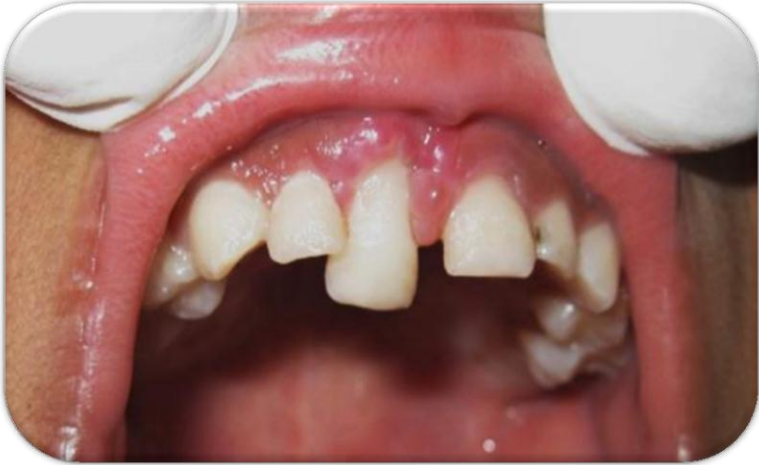

This 2 year old child presented with avulsed 51 and 61 stored in fresh milk within 15 minutes of trauma.

12.1 What is the immediate management of this patient?

12.2 Give reasons.

## Case 13

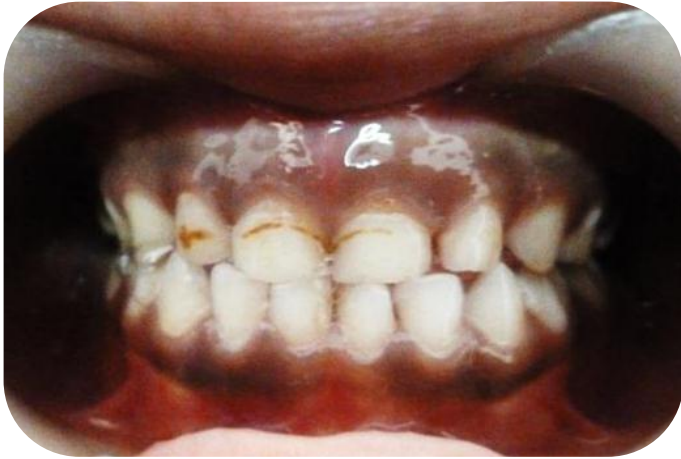

A 4 year old child presented with a history of trauma to the upper front teeth.

13.1 What type of injury do you observe?

13.2 How would you manage this patient?

## Case 14



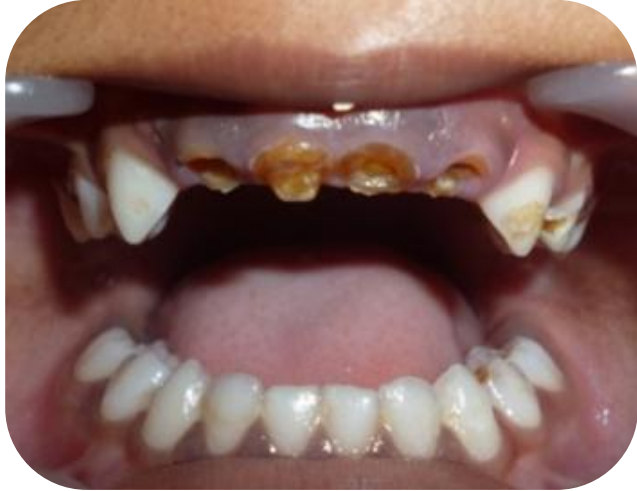This 4 year old child presented with brown discolouration of the upper primary teeth.

14.1 What is the most likely diagnosis?

14.2 Which condition would you exclude prior to arrive at the definitive diagnosis?

14.3 How would you exclude the condition mentioned in 14.2 ?

## Case 15

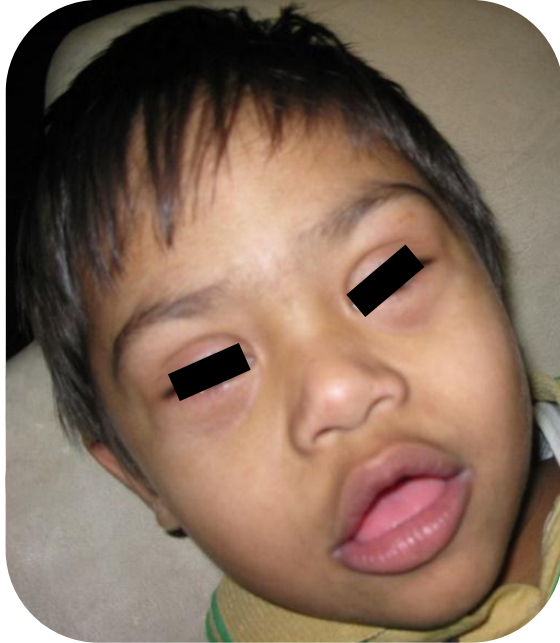

This 4 year old child presented with a complaint of broken upper front teeth with abscesses.

15.1 What is your diagnosis?

15.2 How would you manage the condition?

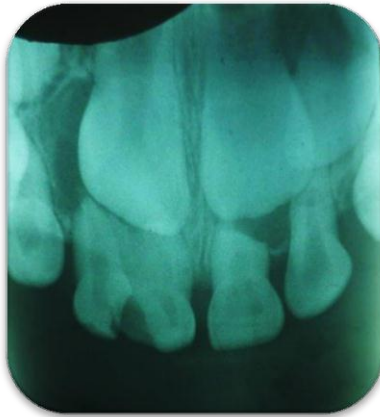
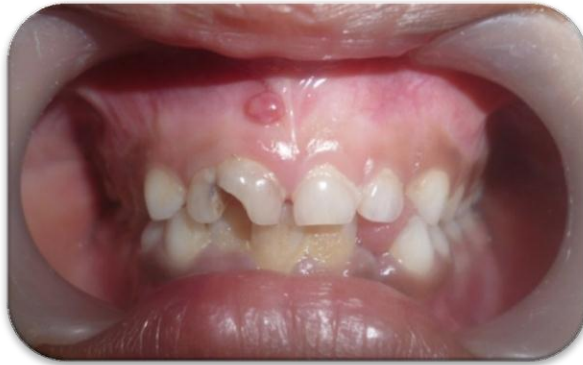## Case 16



- 16.1 Identify the condition that this child is suffering from.
- 16.2 State the general features of the condition.
- 16.3 What are the oral features of this condition?
- 16.4 List the other potential disorders that are associated with the condition mentioned in 16.1.

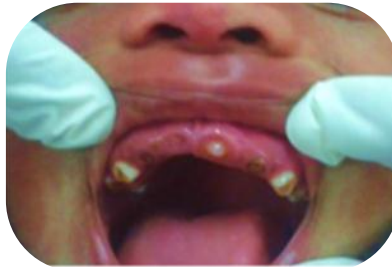
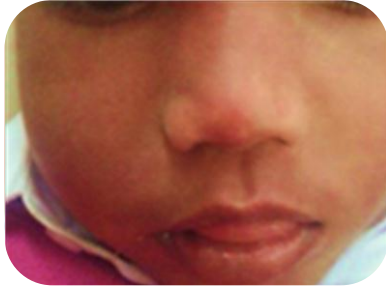
## Case 17



- 17.1 Identify the abnormalities seen in this clinical photograph and in the radiograph.
- 17.2 How would you manage the condition present in upper anterior teeth?

## Case 18

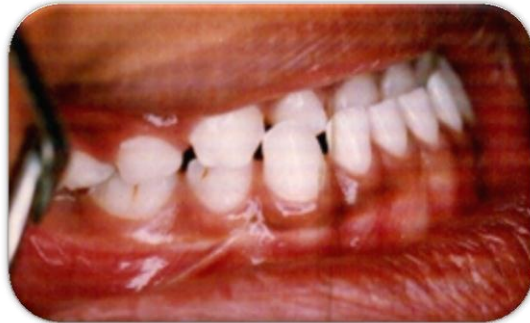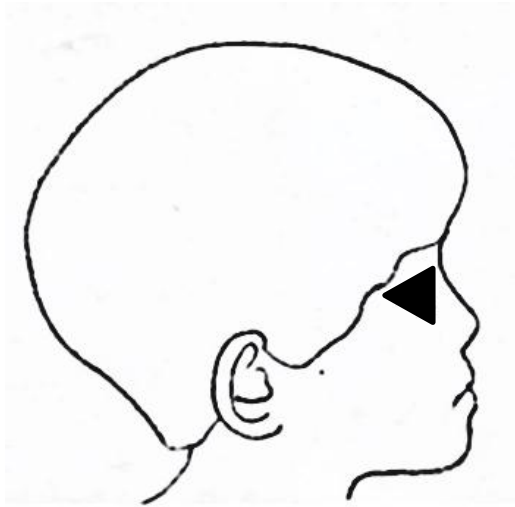


This patient showed multiple carious teeth and port-wine vascular malformation of the right side of the face.

18.1 What is the most likely diagnosis?

18.2 How would you manage the dental condition?

## Case 19

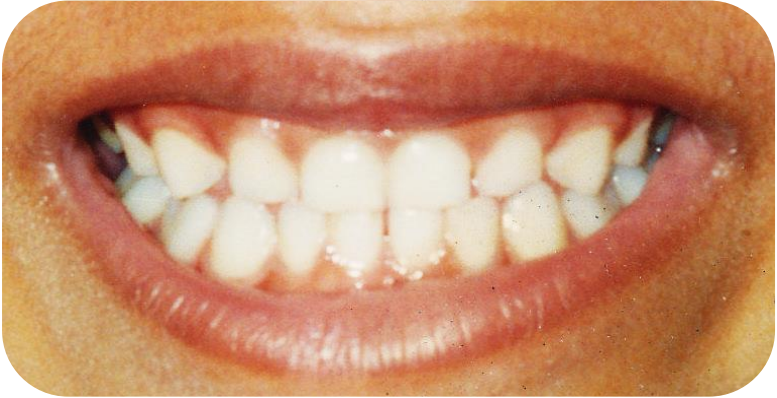

A 5 year old child presented with a malocclusion.

19.1 What is the malocclusion seen?

19.2 Outline the long term treatment plan.

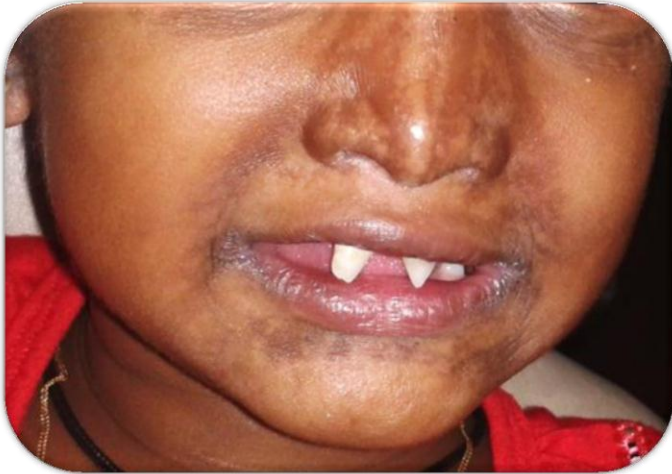## Case 20



This photograph shows the occlusion of primary dentition of a 5 year old child.

What are the age changes that you observe in the anterior teeth of this occlusion?

## Case 21



This is a photograph of a 5 year old child with hypodontia.

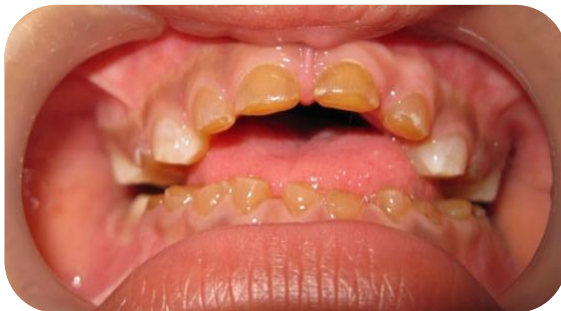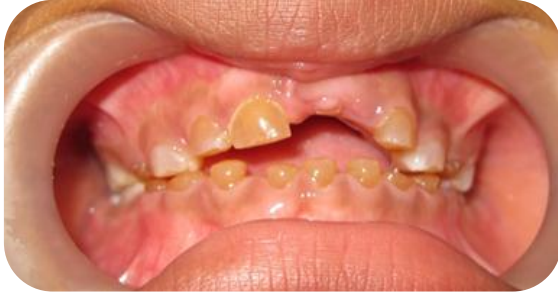21.1 Mention the syndrome that this patient is suffering from.

21.2 State the clinical features of the syndrome.

21.3 State the clinical relevance of this syndrome.

.

## Case 22

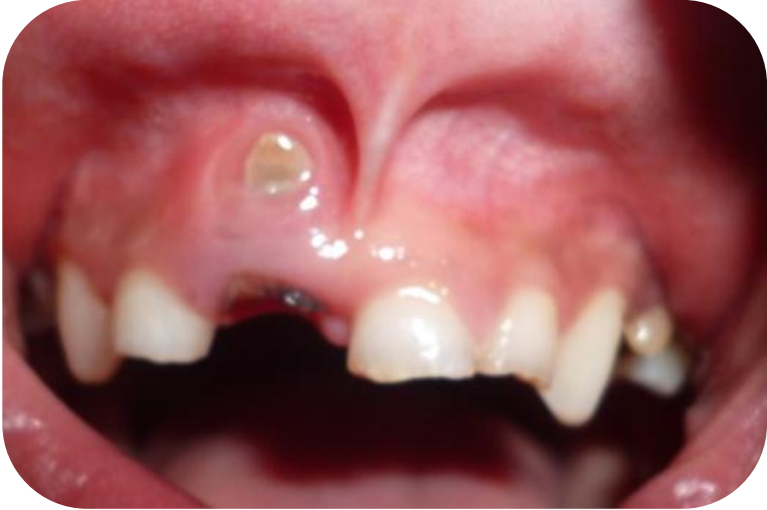

These photographs show the dentitions of identical twins. They presented with a complaint of discoloured teeth.

22.1 What are the differential diagnoses?

22.2 Periapical radiographs showed obliterated root canals.  
State your definitive diagnosis.

## Case 23



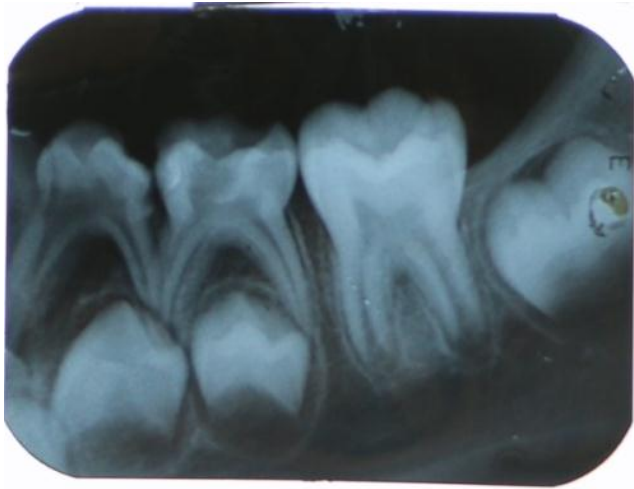
This 5 year old patient presented with a complaint of newly erupting tooth in the labial sulcus.

23.1 What is your tentative diagnosis?

23.2 How would you confirm the diagnosis?

23.3 Outline the management.

## Case 24



This is a radiograph of a 7 year old child patient who presented with a discharging sinus in relation to lower left first primary molar tooth.

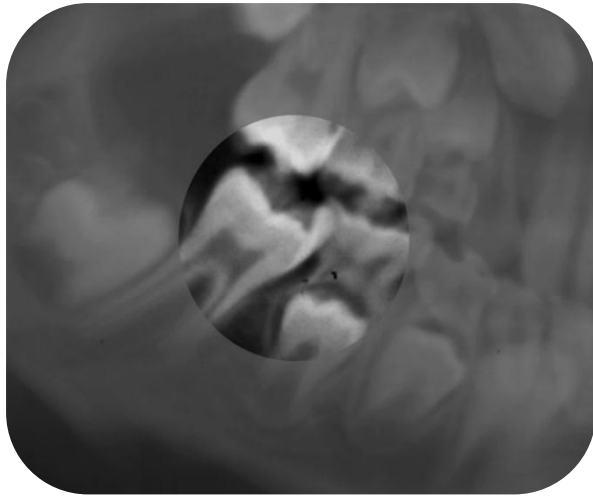24.1 Identify the type of radiograph given.

24.2 List the radiological findings.

24.3 Indicate the treatment plan.



## Case 25



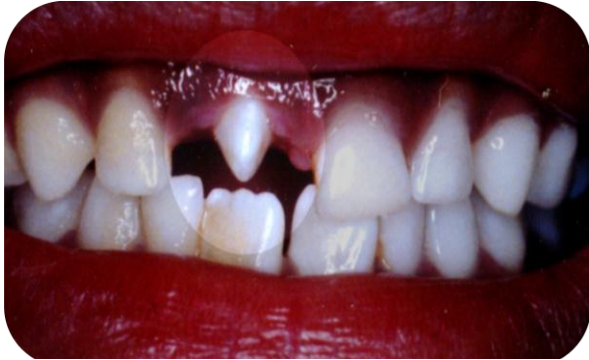The above radiograph is taken from the records of a 9 year old child who presented for Orthodontic treatment.

25.1 Identify the abnormality that is highlighted in the lower jaw.

25.2 How would you correct the abnormality?

25.3 What will be the consequences, if this abnormality goes undetected?

## Case 26



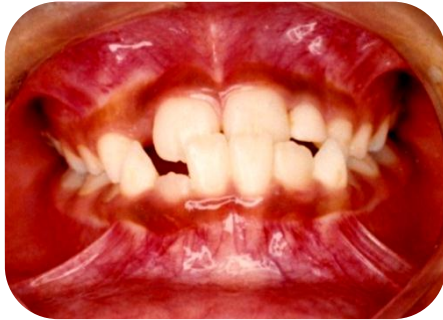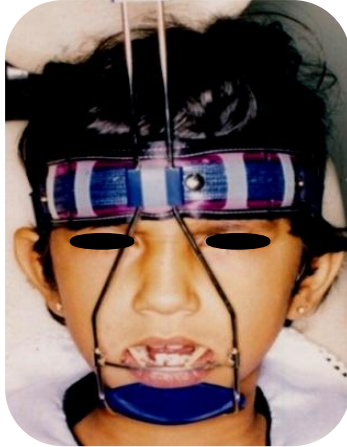A 7 year old child presented with a newly erupted tooth.

26.1 Identify the abnormality in the upper arch.

26.2 Outline your treatment plan.

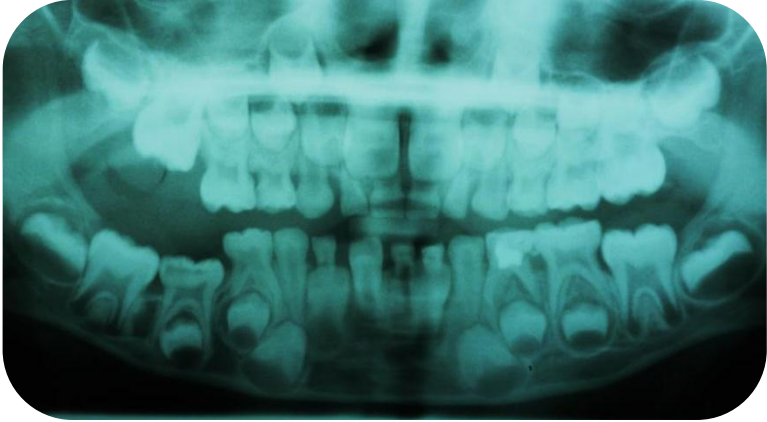
26.3 Why is the incisal edge of 41 irregular?

## Case 27



- 27.1 What is the treatment procedure that has been carried out in this patient?
- 27.2 State the indication for the treatment procedure mentioned in 27.1.
- 27.3 What is the mode of action of this appliance?

## Case 28

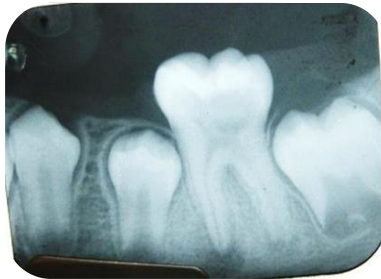
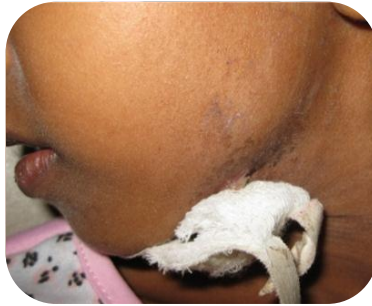
This is a radiograph of an 8 year old child who presented with a complaint of delayed eruption of lower right posterior teeth.

28.1 List the abnormalities that you identify in the radiograph.

28.2 Outline the management.

## Case 29



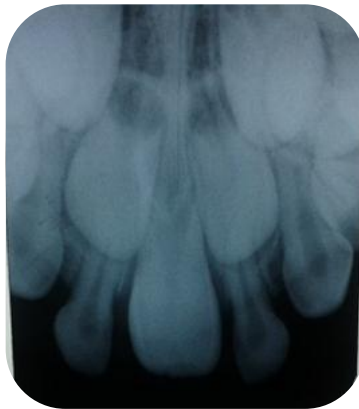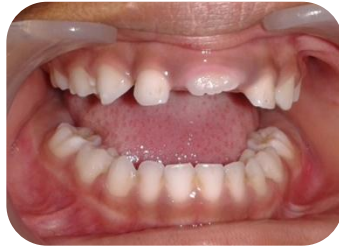This is a photograph of an 8 year old child with an extra-oral discharging sinus at the angle of the mandible on the left side of the face. A radiograph of the region is given.

29.1 Name the type of the radiograph.

29.2 State the abnormalities that you detect in the radiograph.

29.3 Giving reasons, state the treatment that you would suggest.

## Case 30



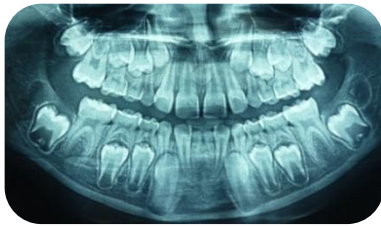
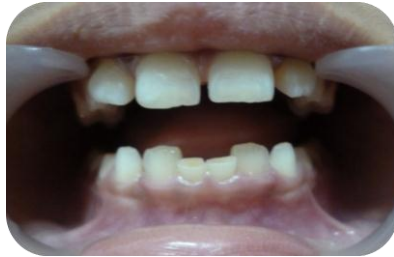This child presented with a single erupting maxillary central incisor. History revealed a similar presentation in the primary dentition.

30.1 Identify the syndrome.

30.2 What is the prevalence of this syndrome?

30.3 List the other features associated with this syndrome.

## Case 31



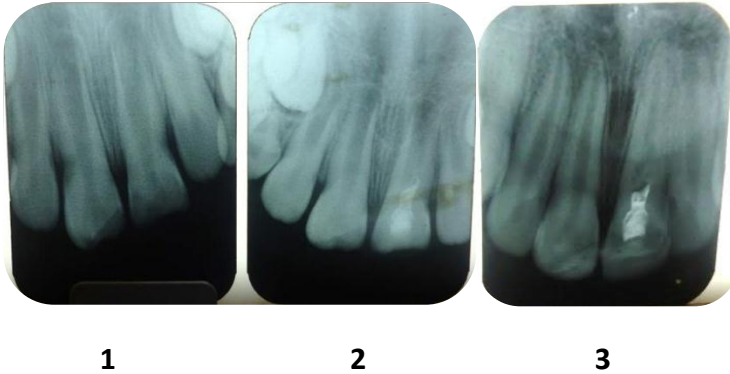
A clinical photograph and a radiograph of a 9 year old child are given.

31.1 Identify the type of the radiograph.

31.2 List the abnormalities that you observe in the upper and lower labial segments.

31.3 State the treatment options.

## Case 32



The first radiograph was taken immediately after trauma to 11 and 21. Second radiograph was taken after the treatment of 21 and the third radiograph was taken two years after the initial treatment.

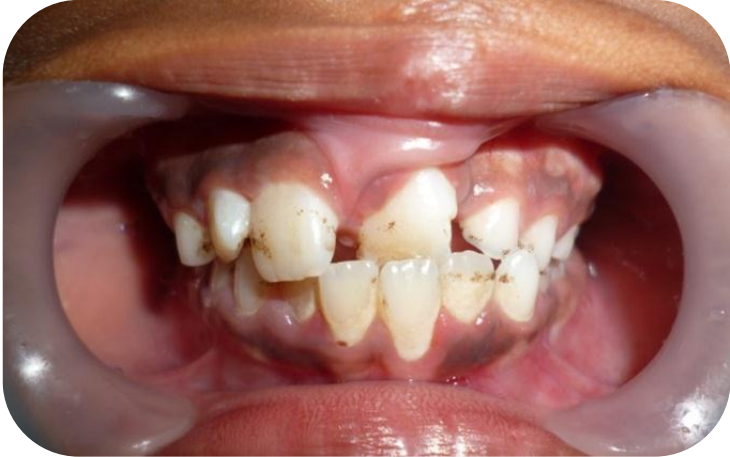32.1 Indicate the type of injuries those are observed.

32.2 Indicate the treatment that has been carried out for 21.

32.3 Explain the outcome of the treatment achieved, by evaluating the third radiograph.



## Case 33

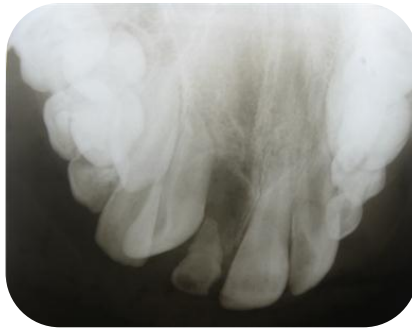
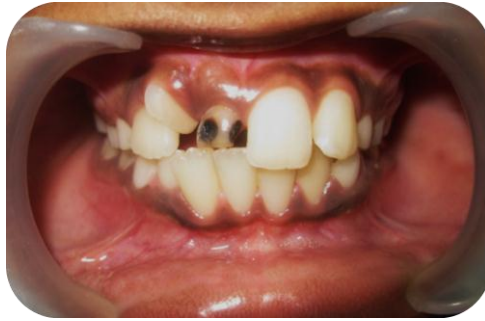
This patient complained of ugly front teeth.

33.1 What are the abnormalities that you detect?

33.2 How would you manage this patient?

## Case 34



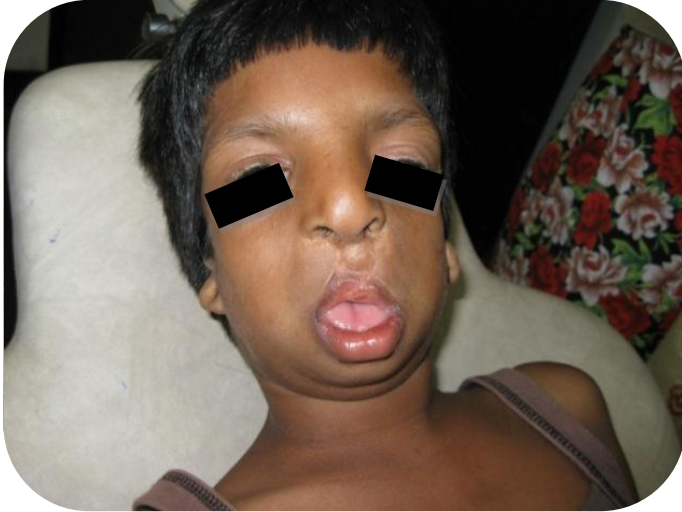This patient complained of a discoloured tooth. A radiograph of upper anterior region is given here.

34.1 Identify the type of radiograph given.

34.2 What are the abnormalities that could be identified clinically and radiologically?

34.3 How would you manage the abnormalities?

## Case 35



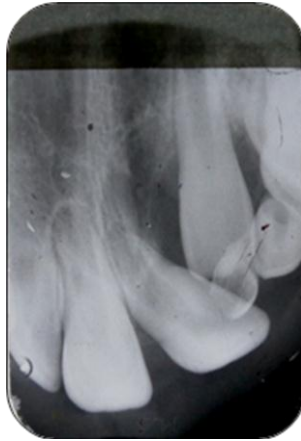
This child with a rare syndrome presented for dental treatment.

35.1 Identify the syndrome.

35.2 List the characteristic features associated with this syndrome.

35.3 What type of dental treatment would be required for this child?

## Case 36



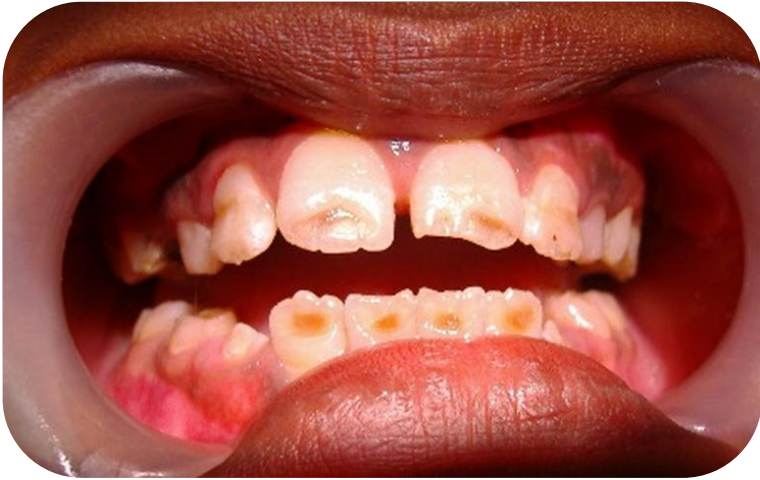This is a periapical radiograph of a child who presented with irregular upper left labial segment.

36.1 What are the radiological findings seen in 21 and 22 region?

36.2 Explain how this kind of irregularity develops.

36.3 What will be the consequences of the abnormality, if it is not detected early?

## Case 37



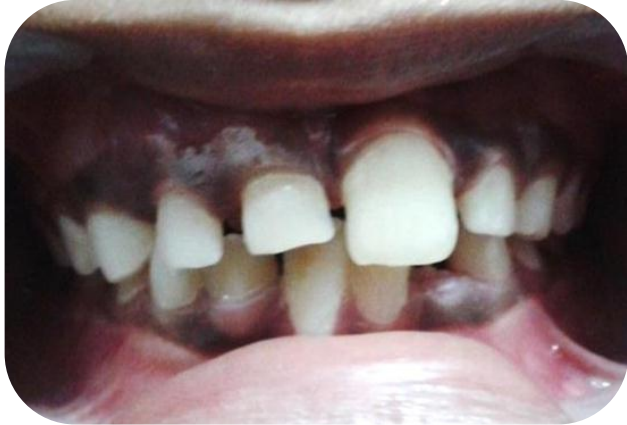This 8 year old child presented with a complaint of discoloration of teeth.

37.1 What is your diagnosis?

37.2 How would you confirm the diagnosis?

37.3 Outline the treatment plan.

## Case 38



An 8 year old child presented with a complaint of unaesthetic newly erupted 21.

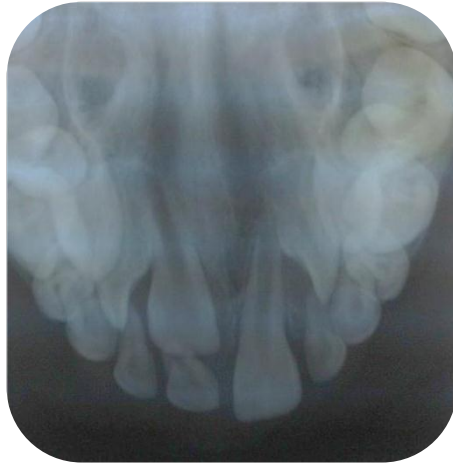
38.1 What is the abnormality that you detect?

38.2 What investigations would you carry out to confirm the diagnosis?

38.3 List three causes that may give rise to the abnormality mentioned in 38.1.

38.4 Explain giving reasons the findings that you observe to the parents.

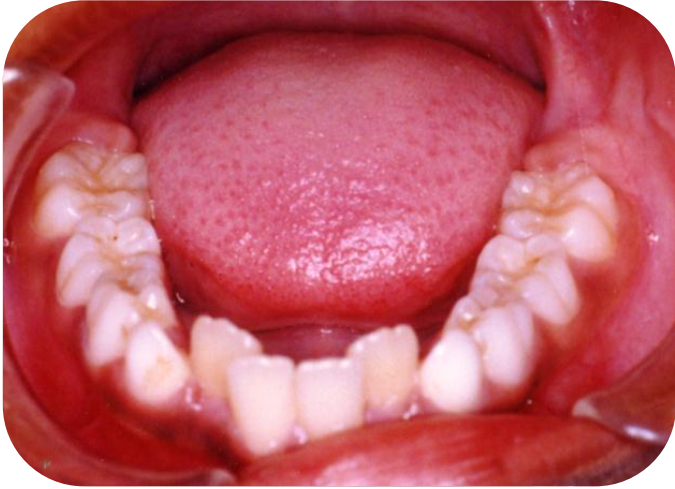## Case 39



This is an upper standard occlusal radiograph of the child mentioned in question number 38.

How would you manage the abnormality?

## Case 40



A 9 year old child requested correction of irregularity of lower front teeth.

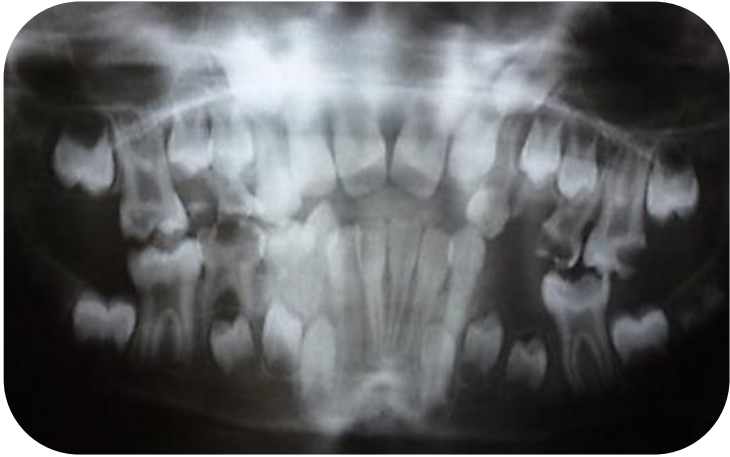40.1 What is the irregularity seen in the lower labial segment?

40.2 What advice would you give to the anxious parents regarding this irregularity?

40.3 What are the precautions that you would take to prevent worsening of this irregularity?



## Case 41



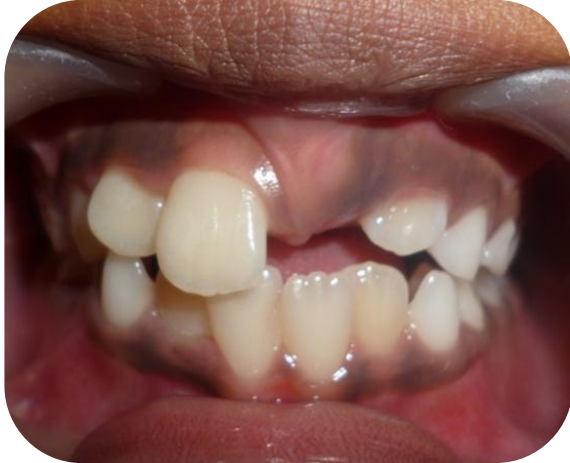This is a radiograph of a child, who presented with many grossly broken and pulp exposed teeth.

41.1 Name the type of the radiograph given.

41.2 Name one developmental anomaly that you observe in the radiograph of teeth.

41.3 State the clinical implications of the abnormality mentioned in 41.2.

## Case 42

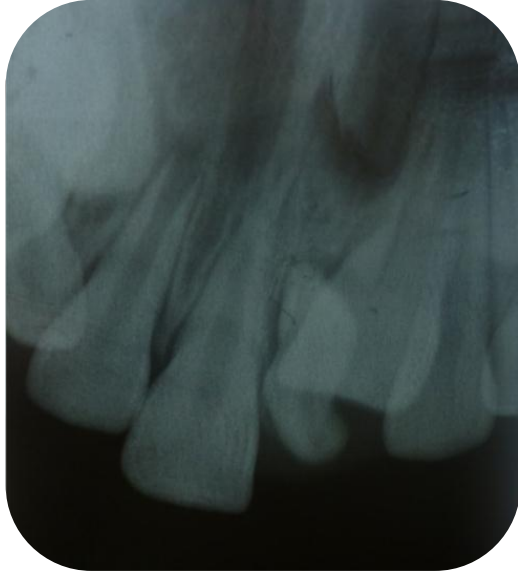

A 9 year old child presented seeking advice regarding his upper front teeth.

42.1 What is the abnormality that you observe?

42.2 Give the possible contributory factors for the abnormality mentioned in 42.1.

## Case 43

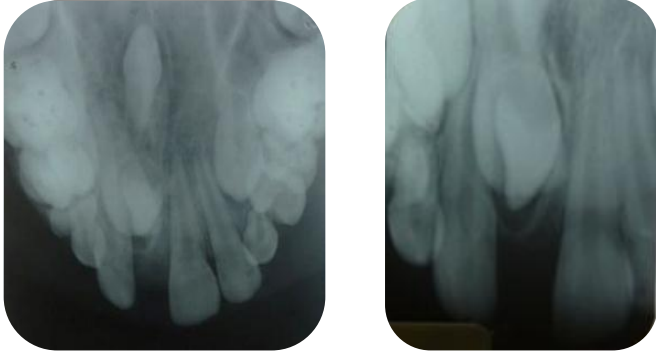


This is the periapical radiograph of the patient mentioned in question number 42.

43.1 Give the definitive cause for the delayed eruption of 21.

43.2 Outline the management strategies.

## Case 44

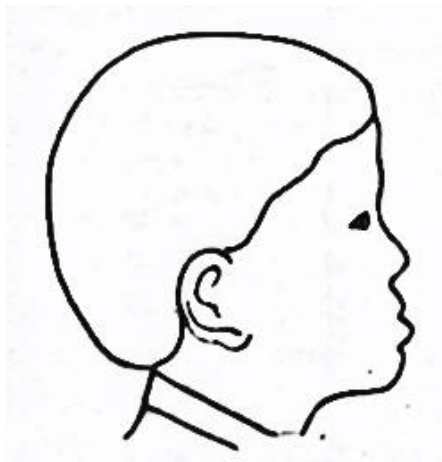
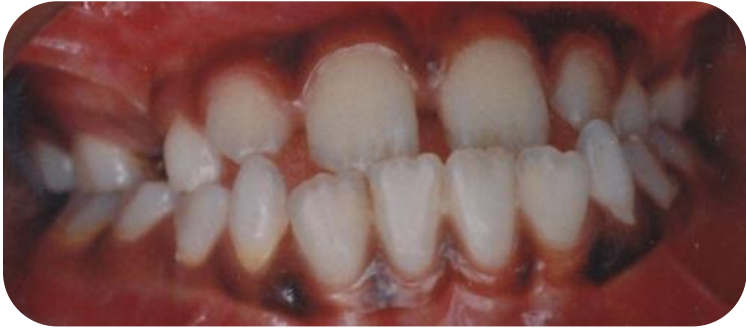
44.1 What is the abnormality that you detect in the radiographs?

44.2 What is the prevalence of the abnormality mentioned in 44.1?

44.3 How would you manage this patient?

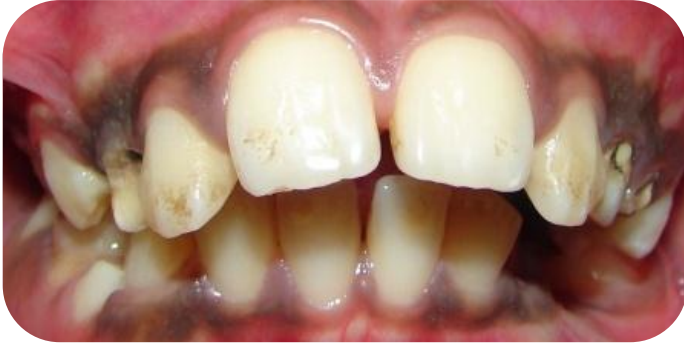## Case 45



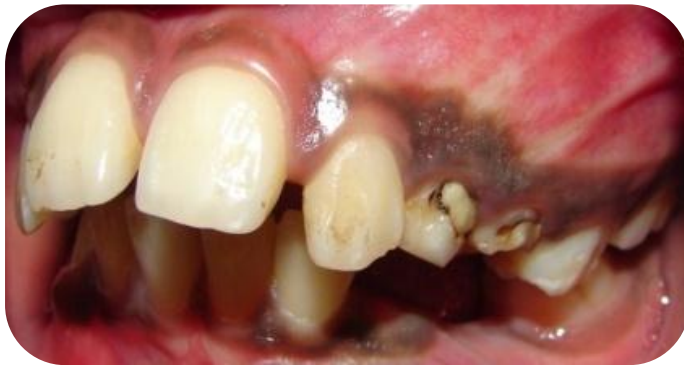45.1 What are the occlusal abnormalities seen in the labial segments?

45.2 What are the possible causes for each irregularity?

## Case 46



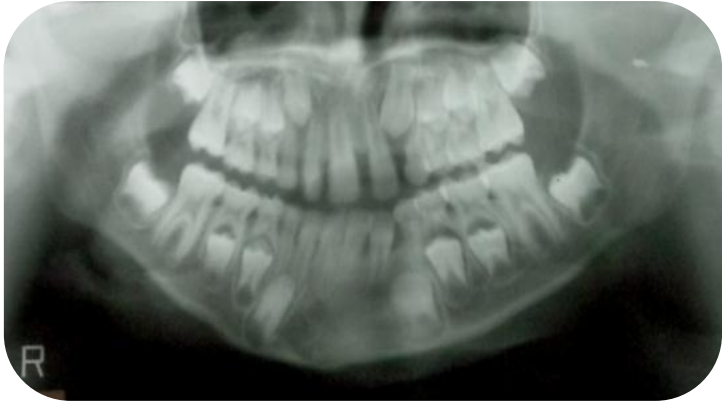Front view



Left view

- 46.1 List the occlusal irregularities seen on the left side of this occlusion.
- 46.2 What is the approximate age of this patient?
- 46.3 Give reasons for the irregularity of 22.

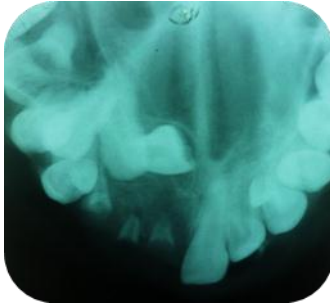
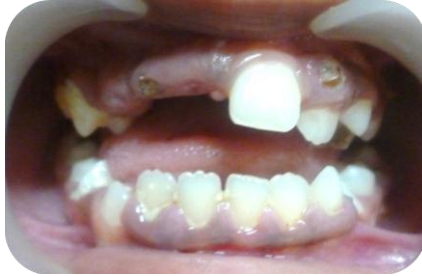## Case 47



This is a radiograph of a child who presented with spacing in the upper labial segment.

- 47.1 What is the approximate age of this child?
- 47.2 Which tooth is missing in the upper labial segment?
- 47.3 How would you close the space?

## Case 48



A 10 year old child presented with delayed eruption of permanent upper anterior teeth. She gave a history of trauma to primary teeth at the age of one year. Upper standard occlusal radiograph is given.

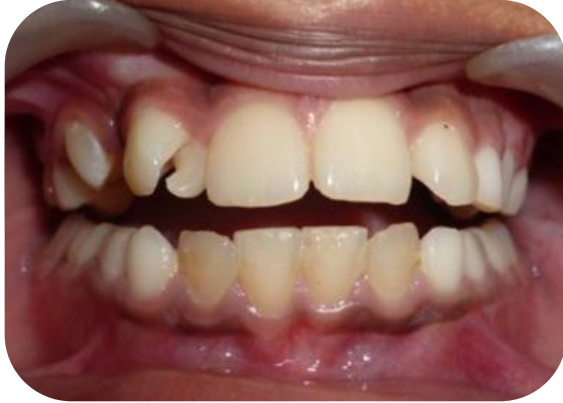48.1 Identify the abnormalities found in the upper arch.

48.2 What could be the reason for this presentation?

48.3 State the management of the condition.



## Case 49



This 10 year old child presented with a complaint of an abnormal tooth.

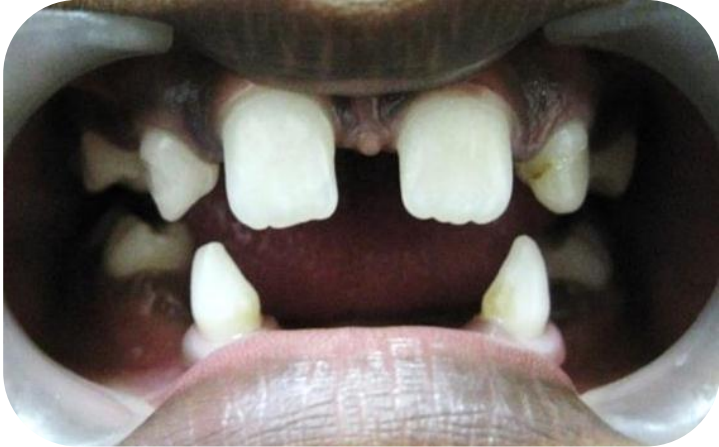49.1 What are your differential diagnoses?

49.2 How would you confirm the diagnosis?

49.3 What is the clinical significance of this abnormality?

49.4 How would you manage this abnormality?

## Case 50



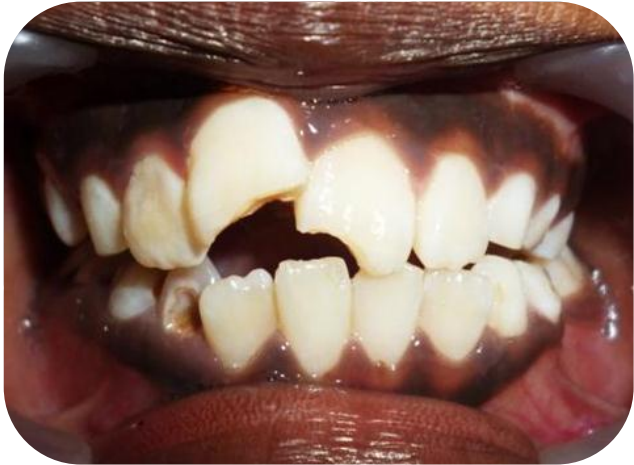This 10 year old child presented to the clinic with a complaint of missing teeth. The radiograph revealed the presence of six permanent teeth.

50.1 What is the abnormality that you detect in this child?

50.2 What are the other changes that you would expect to see in this child?

50.3 Name the condition that is associated with the changes that you list in 50.2.

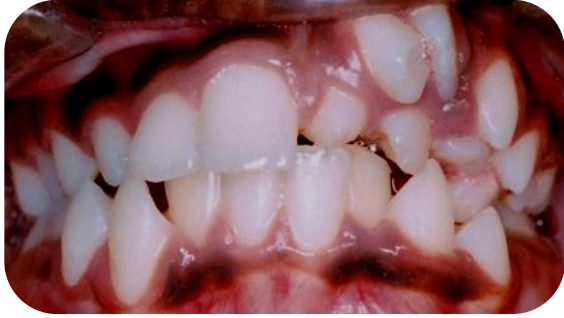## Case 51



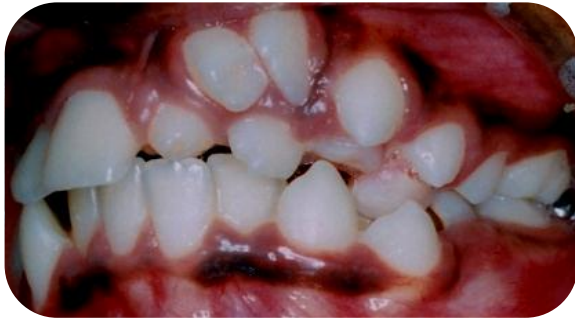This patient presented to the clinic immediately after a fall with an uncomplicated crown fractures of 11 and 21. The fracture of 11 extends very close to the pulp.

How would you manage the traumatized teeth?

## Case 52



**Front view**



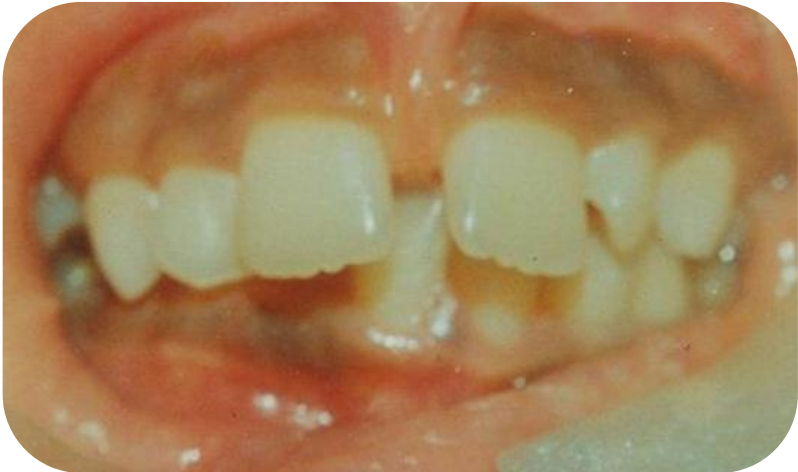**Left view**

A 10 year old child presented with crowding.

52.1 What are the abnormalities that you detect on the left side?

52.2 How would you manage this patient?

## Case 53

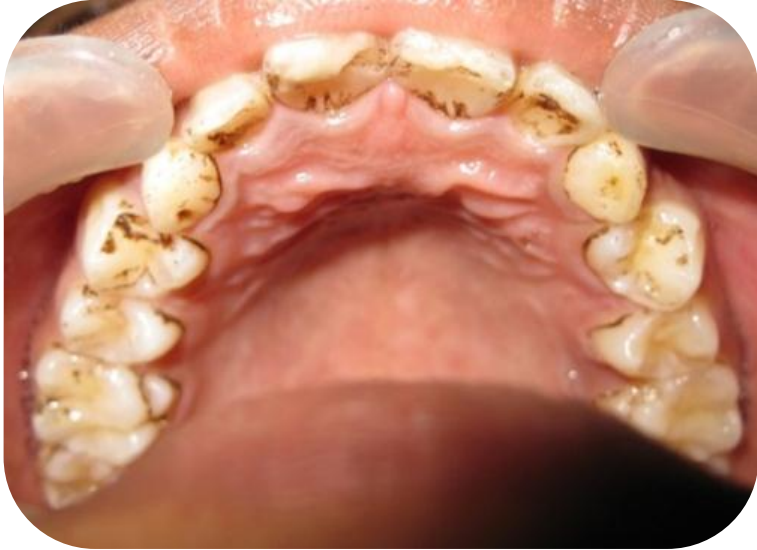

A 10 year old child presented with a complaint of irregular front teeth.

53.1 What are the abnormalities that you observe in the upper labial segment?

53.2 Outline your treatment plan.

## Case 54

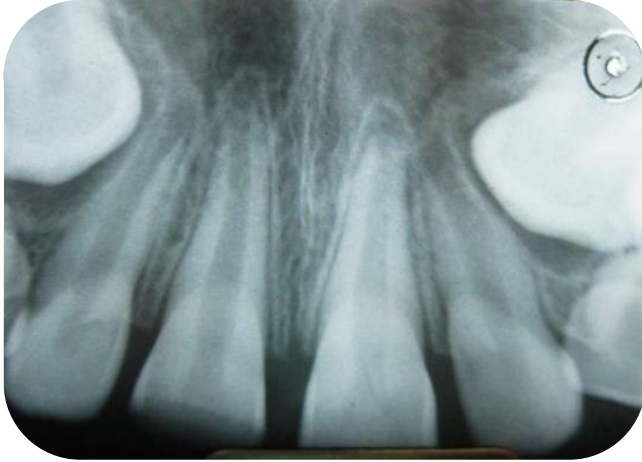

This 11 year old patient presented with a complaint of discoloured teeth.

54.1 What are your observations?

54.2 How would you manage the conditions mentioned in 54.1?

## Case 55



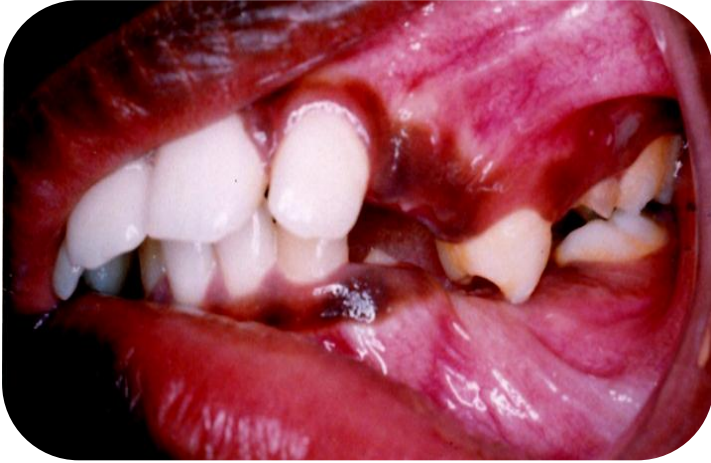This is a periapical radiograph of a child with a complaint of trauma to 11.

55.1 What is the diagnosis?

55.2 What are the treatment options?

55.3 What factors will determine the best treatment modality for 11?

## Case 56



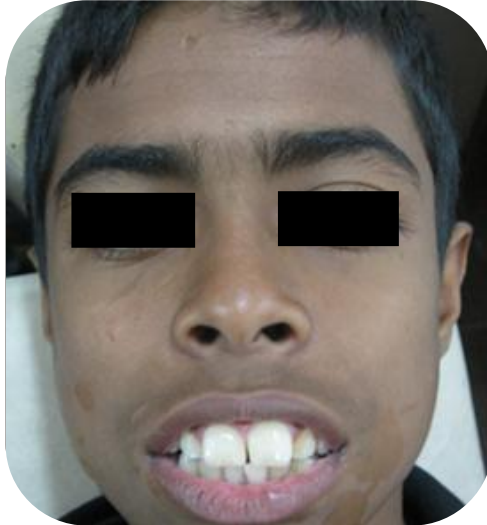A child in mixed dentition stage with a history of premature loss of primary molar teeth presented for Orthodontic treatment.

56.1 What is the abnormality that you observe in the left buccal occlusion?

56.2 What are the precautions that you could have taken to prevent the abnormality mentioned in 56.1?



## Case 57



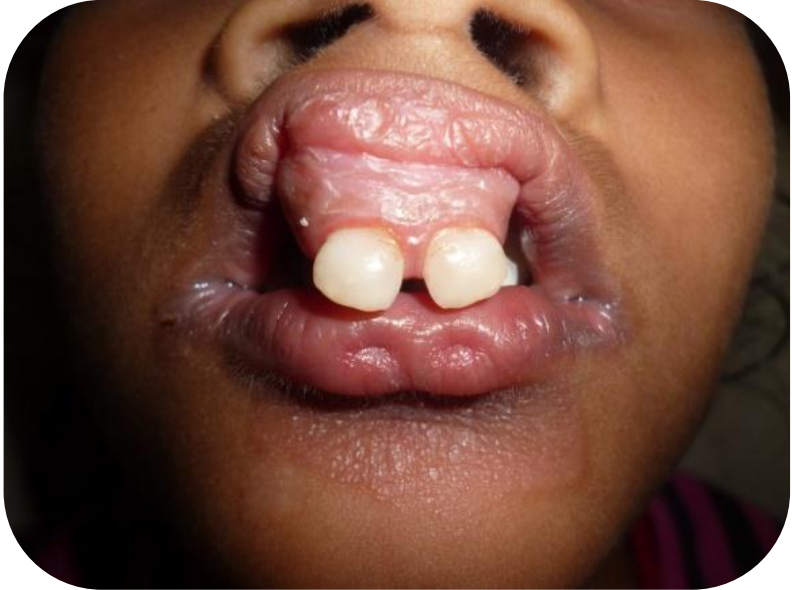This 11 year old child presented with a complaint of disproportionate anterior teeth.

57.1 What is your diagnosis?

57.2 What is the prevalence of this condition?

57.3 How would you manage the patient?

## Case 58

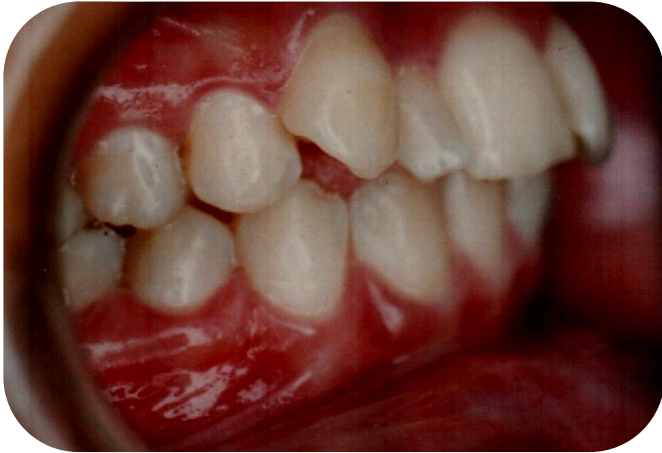

This 12 year old girl presented with a complaint of carious teeth.

58.1 What are the abnormalities seen in this patient?

58.2 What is the diagnosis?

## Case 59



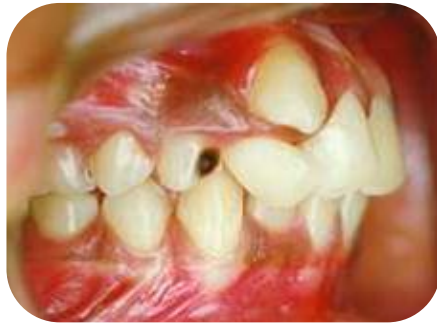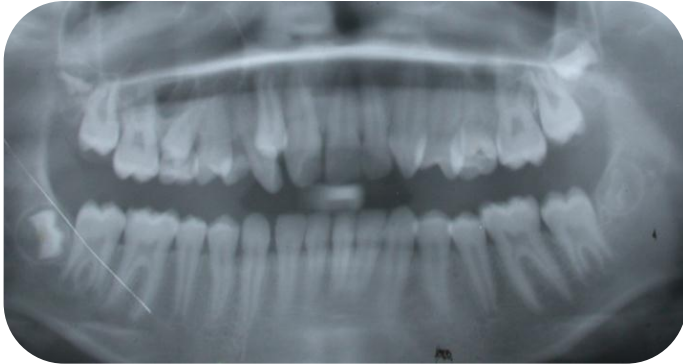A 12 year old girl requested correction of irregularity of upper front teeth.

59.1 What are the occlusal irregularities seen on the right side of this malocclusion?

59.2 What are the steps you could have taken in the mixed dentition stage to prevent establishment of this malocclusion?

59.3 Outline your treatment plan.

## Case 60



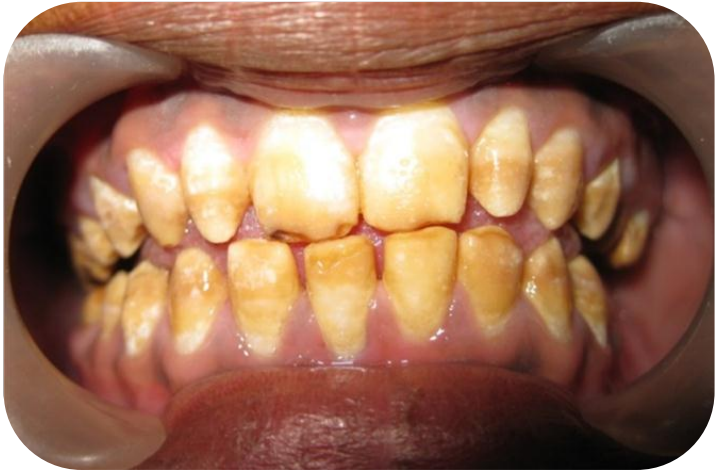A 12 year old girl complained of irregular upper front teeth.

60.1 What are the irregularities seen in the right side of the upper arch?

60.2 What is the precaution that you could have taken to prevent the development of this malocclusion?

60.3 Outline the treatment plan.

## Case 61

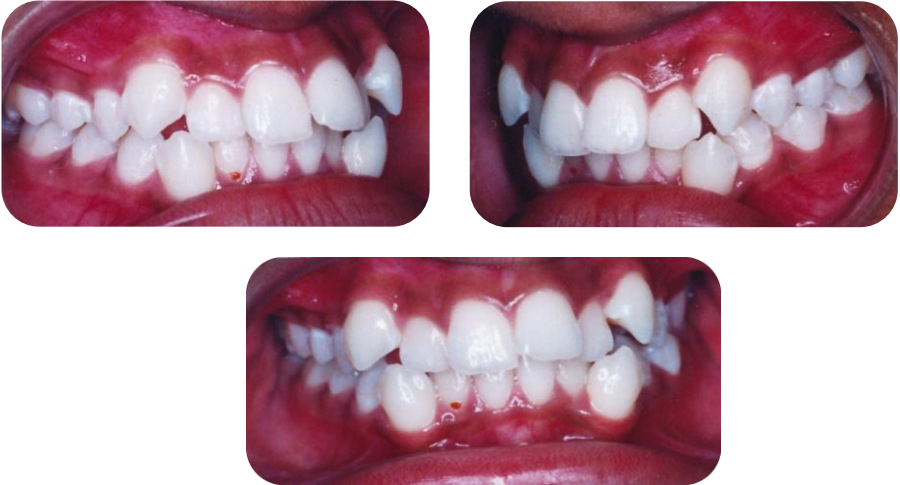

A 13 year old boy presented with a complaint of discoloured teeth.

61.1 What are your differential diagnoses?

61.2 What additional information would you gather from the history in order to arrive at the definitive diagnosis?

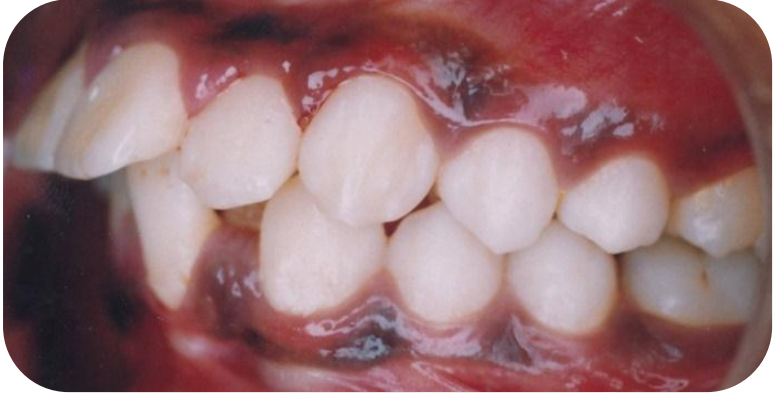## Case 62



The photographs show three different views of occlusion of the same patient.

- 62.1 Indicate the angulation that you observe in each permanent canine.
- 62.2 Indicate the type of tooth movement that is necessary for distal movement of canines, with different angulations.

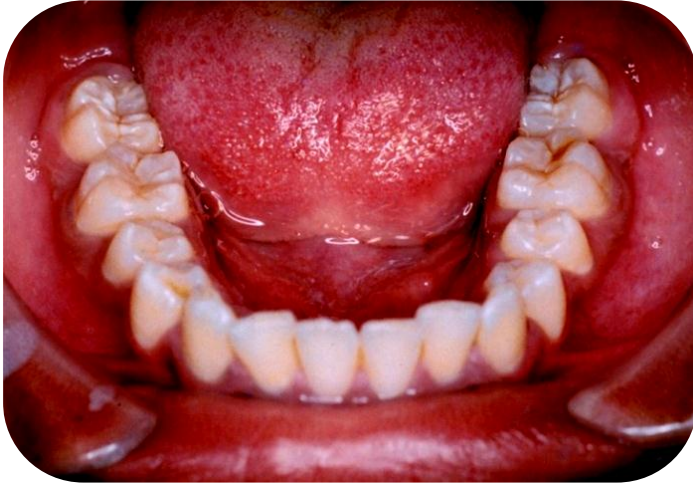## Case 63



Observe this occlusion.

- 63.1 What is the Molar Relationship and Canine Relationship seen in the left side of this malocclusion?
- 63.2 What is the overall classification of the malocclusion?
- 63.3 What additional information would you require to arrive at the final diagnosis?

## Case 64



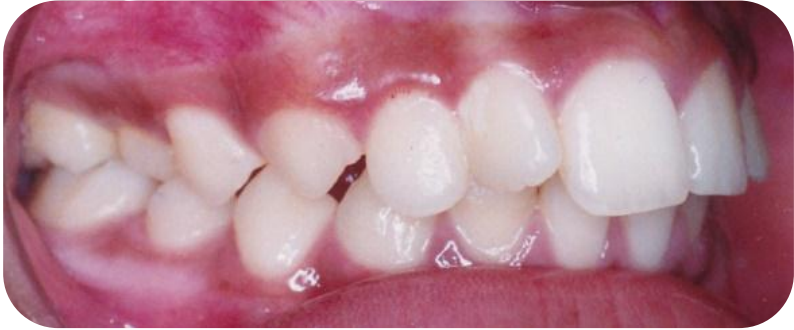A 14 year old patient presented with Class I mild malocclusion. As the malocclusion is very negligible, no treatment was offered.

64.1 Explain the long term changes that you would expect in the alignment of lower incisors.

64.2 Indicate the scientific basis for your Answer.



## Case 65

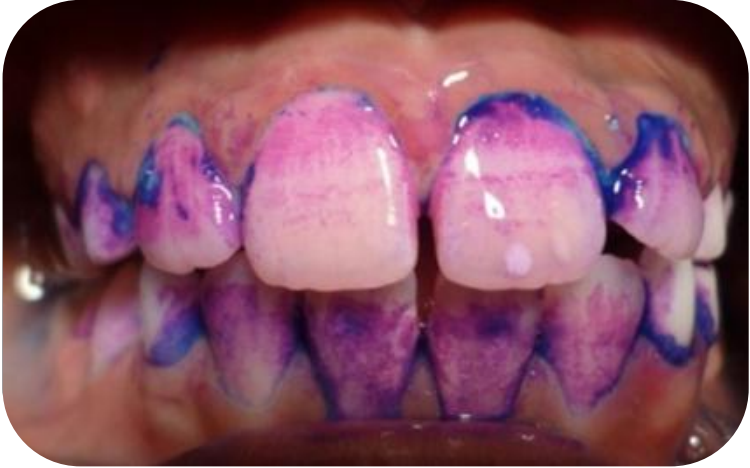

This 12 year old boy requested orthodontic treatment.

65.1 What are the occlusal abnormalities seen in the right side of the upper arch?

65.2 How would you manage this patient?

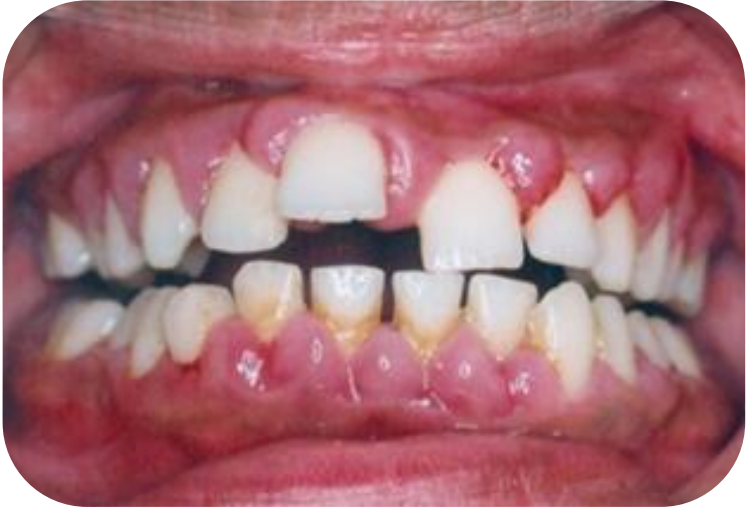## Case 66



This photograph shows a dental procedure carried out in a 13 year old patient.

- 66.1 Name the procedure that has been carried out in this child.
- 66.2 What is the material that has been used in the procedure mentioned in 66.1?
- 66.3 State the advantages of its use.
- 66.4 List the different products available in the market.

## Case 67



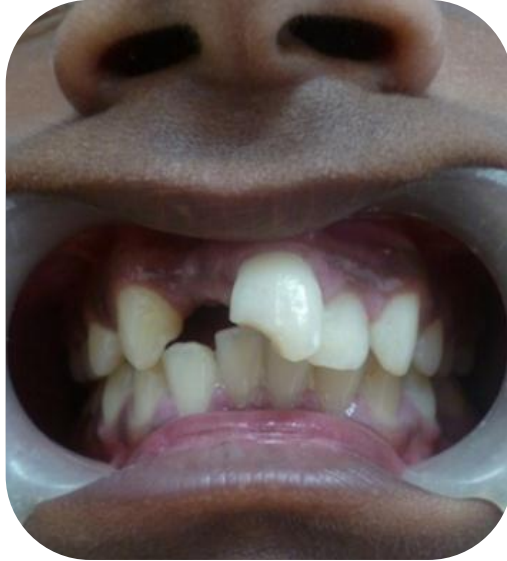This 13 year old child presented with a complaint of drifting of teeth and bleeding gums.

67.1 What are your differential diagnoses?

67.2 How would you confirm the diagnosis?

67.3 How would you manage this patient?

## Case 68

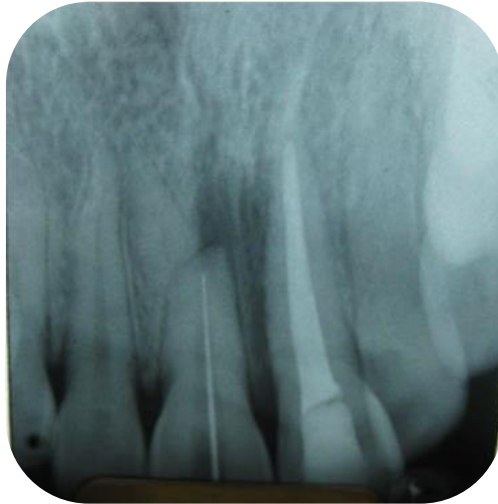

This 13 year old patient presented with a history of avulsed 11 and 12, of 6 month duration.

68.1 What abnormalities do you observe in this patient?

68.2 How would you manage this patient?

## Case 69

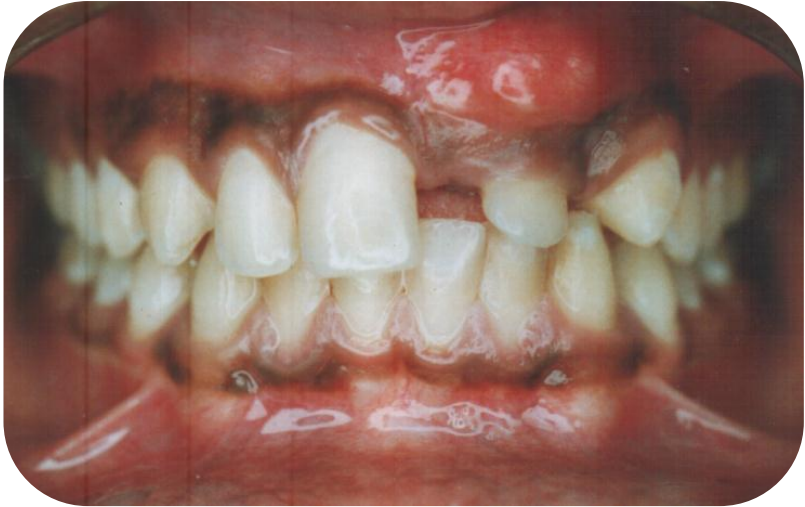

This radiograph was taken to estimate the working length of 11 which was non vital.

69.1 List the radiological findings.

69.2 How would you treat 11?

## Case 70



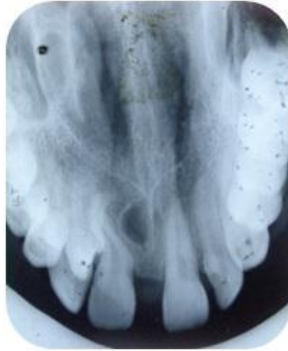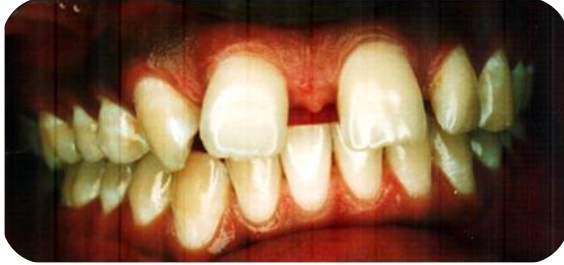Observe the upper labial segment of this malocclusion.

70.1 What are the occlusal irregularities that you observe?

70.2 What are the possible causes of the above irregularities?

70.3 Outline your treatment plan.

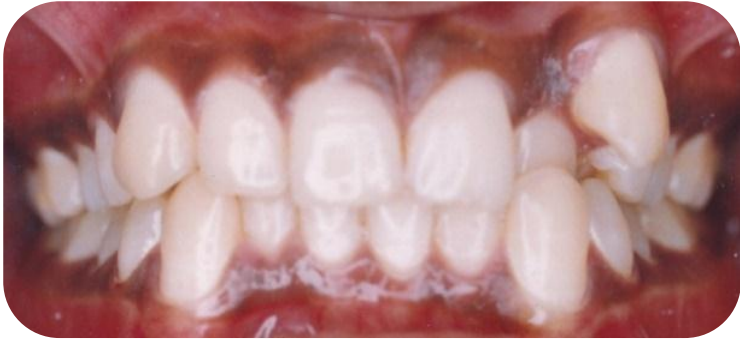## Case 71



A 16 year old patient presented for correction of the space between upper front teeth.

- 71.1 What is the most likely diagnosis of the lesion observed in the radiograph?
- 71.2 How does the irregularity seen in the upper labial segment develop?
- 71.3 How do you move teeth to close the space in the upper labial segment?
- 71.4 Give reasons for the Answer mentioned in 71.3.

## Case 72



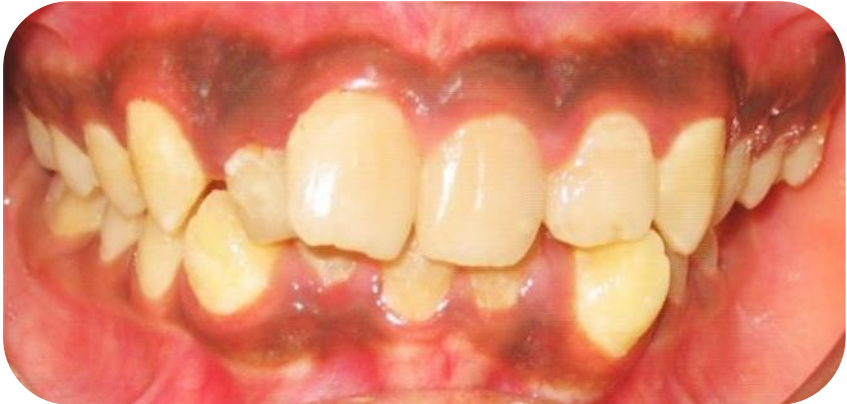This is the front view of the occlusion of a 13 year old boy who presented for Orthodontic treatment.

72.1 Identify the occlusal irregularities seen in the upper labial segment.

72.1 Explain the possible contributory factors to the development of malocclusion.



## Case 73



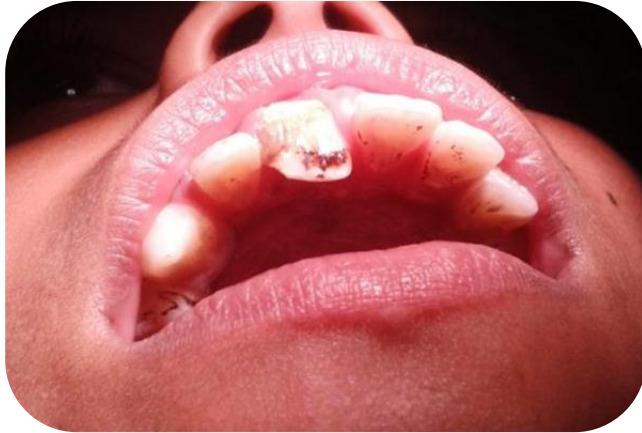A 15 year old boy presented for correction of malocclusion.

73.1 What are the occlusal irregularities seen in the labial segments of this patient?

73.2 What is the appliance of choice for correction of this malocclusion?

73.3 Give reasons for the Answer given in 73.2.

## Case 74



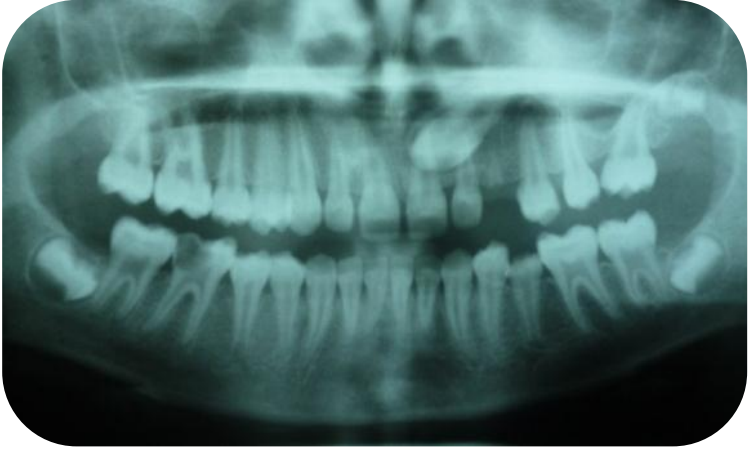This patient presented with an abnormal 11. He gave a history of trauma to the front teeth in childhood.

74.1 What are the abnormalities that you detect in 11?

74.2 What are the clinical implications of these abnormalities?

74.3 How would you manage 11?

## Case 75

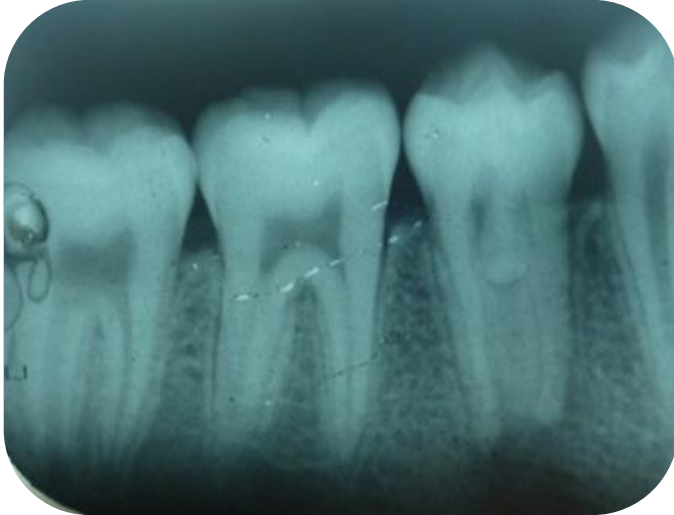

75.1 State the radiological findings.

75.2 Outline the treatment plan for 23.

75.3 What is the approximate age of this patient?

## Case 76

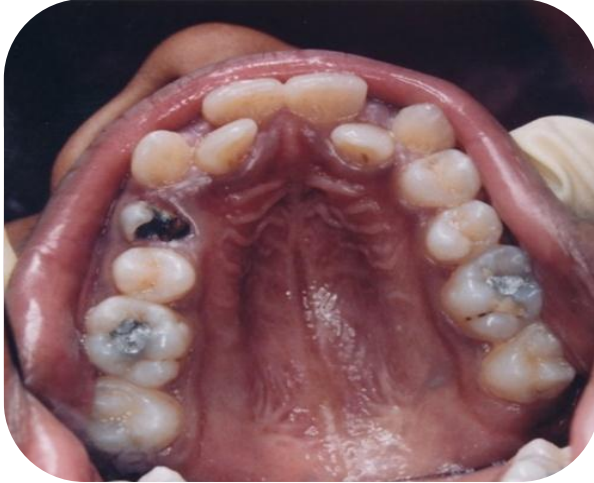


This is a radiograph of a patient who complained of a periapical abscess in relation to 45 which is non-vital.

76.1 What is your diagnosis?

76.2 How would you manage 45?

## Case77



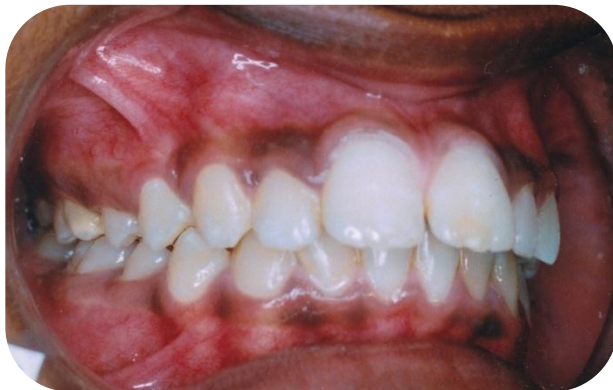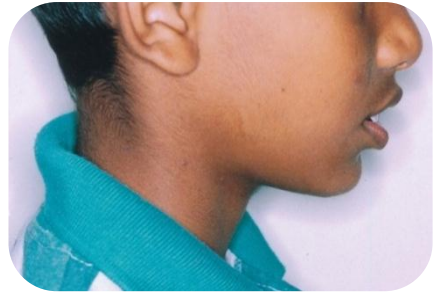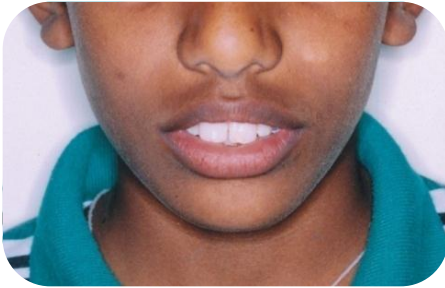
This is an occlusal view of the upper arch of a 14 year old patient.

77.1 What are the obvious irregularities of the alignment of upper labial segment?

77.2 Which teeth would you select for extraction, in order to correct the malocclusion?

77.3 Justify your Answer given in 77.2.

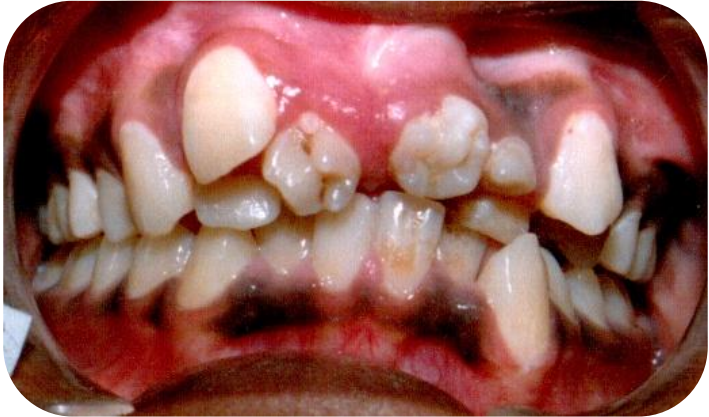## Case 78



78.1 What is the malocclusion seen?

78.2 What are the contributory factors for the development of the malocclusion?

## Case 79



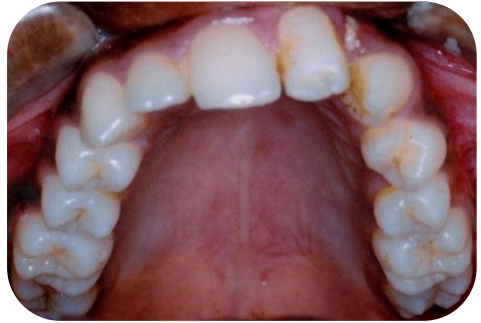
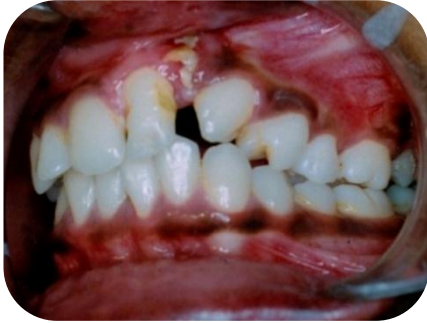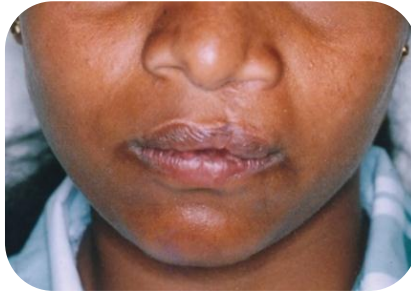A 14 year old boy presented with abnormal upper front teeth.

79.1 What is the cause of the abnormality seen in the upper labial segment?

79.2 List the steps taken in the management of the malocclusion.

79.3 Give reasons for the Answer given in 79.2.

## Case 80

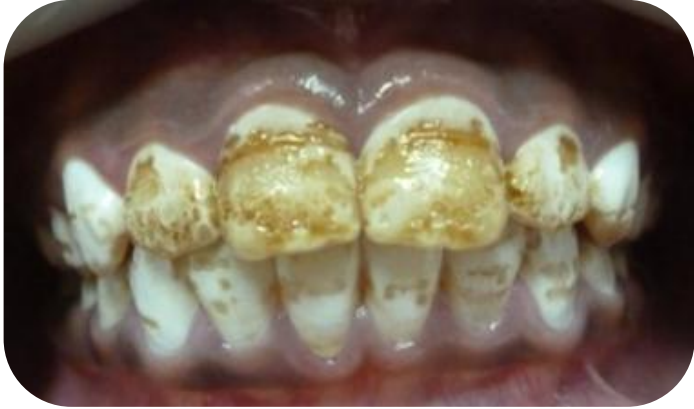

This 13 year old girl who had undergone surgical repair of the cleft lip presented for Orthodontic treatment.

- 80.1 What are the residual facial features which need surgical revision?
- 80.2 What are the dental irregularities seen in the upper labial segment?



## Case 81



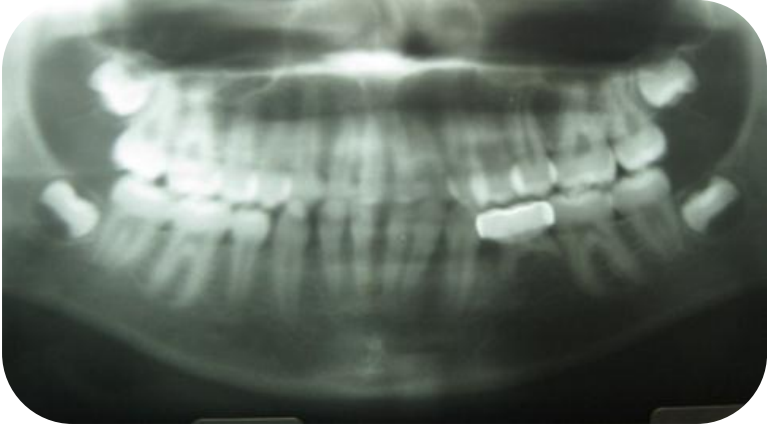This is a photograph of a 14 year old child from Kurunegala, who presented with a complaint of discoloured teeth.

81.1 What is the most likely diagnosis?

81.2 Give reasons for the Answer mentioned in 81.1.

81.3 State the different stages of this condition.

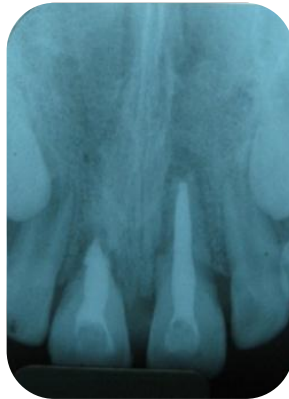
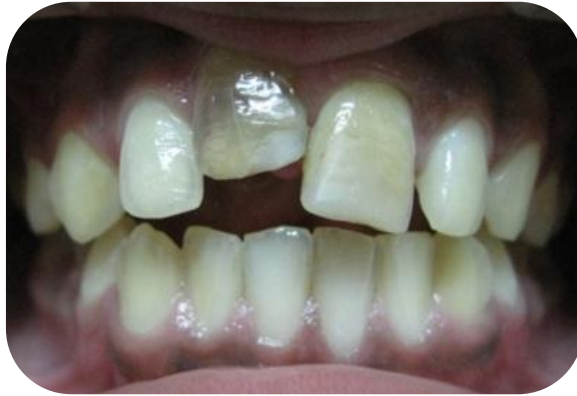## Case 82



82.1 Identify the teeth present in this radiograph.

82.2 Give the approximate age of the patient.

## Case 83

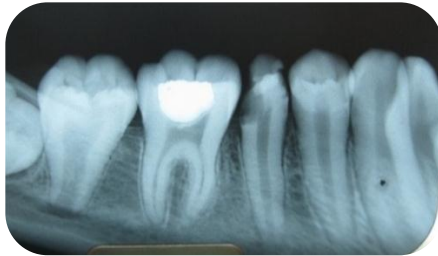
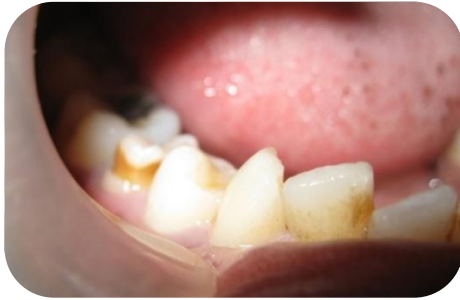

A 15 year old boy presented with a history of mobile 11. He gave a history of replantation of 11. A recently taken periapical radiograph is given.

83.1 What are the abnormalities that you detect?

83.2 Outline the treatment plan.

## Case 84



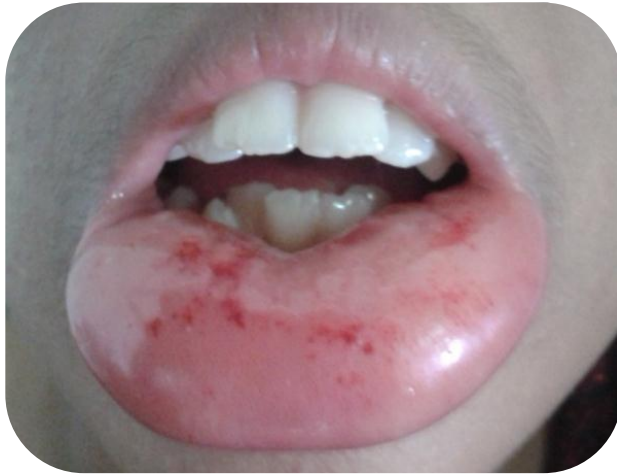This 15 year old child present with intermittent pain in relation to 45. The periapical radiograph is given.

84.1 What is the abnormality that you detect on 45?

84.2 Comment on the radiographic findings.

84.3 How would you treat 45?

## Case 85

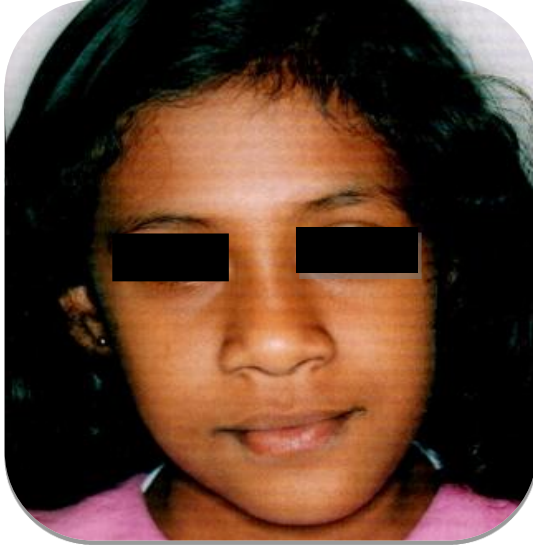

A 15 year old child presented four hours following bilateral dental extractions in the lower arch for Orthodontic purpose.

85.1 Give your tentative diagnosis.

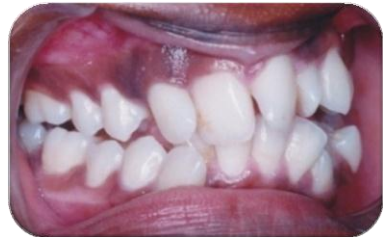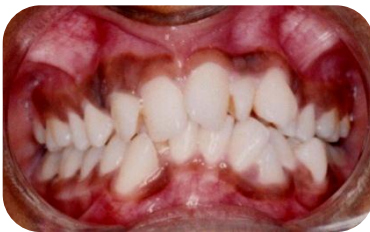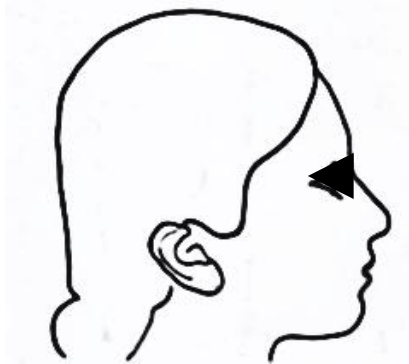85.2 How would you manage this patient?

## Case 86



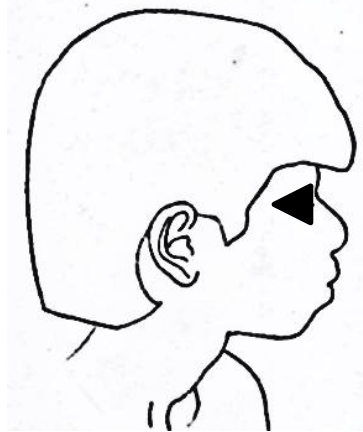
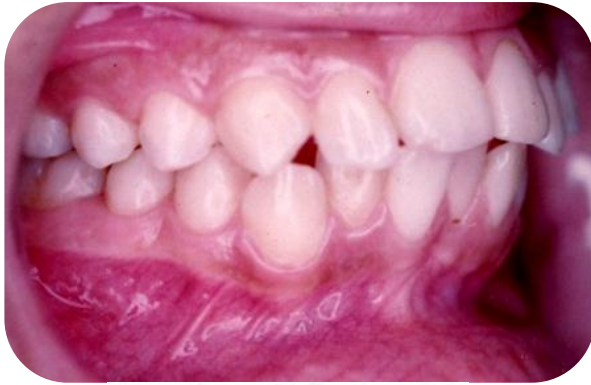- 86.1 What is the abnormality seen in the transverse dimension of this face?
- 86.2 Give a possible cause of this abnormality.
- 86.3 What is the investigation that you would carry out to confirm the diagnosis?
- 86.4 Outline the treatment plan.

## Case 87



- 87.1 Determine the antero-posterior and vertical relationship of the skeletal bases by observing the facial profile.
- 87.2 Describe angulation of the lower incisors.
- 87.3 State the reason for mesio- palatal rotation of 16.

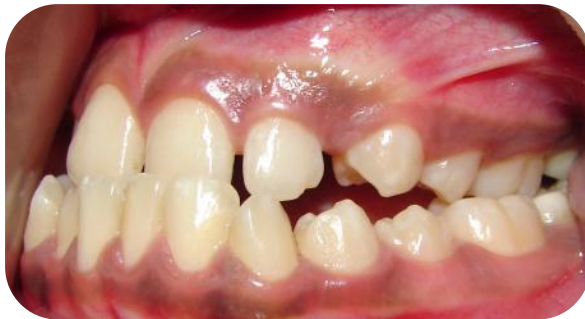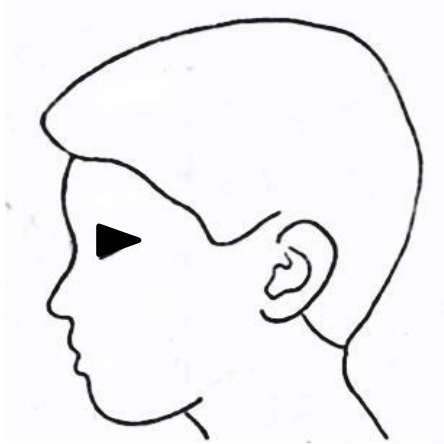
## Case 88



- 88.1 What are the Incisor, Canine and Molar Relationships of this patient?
- 88.2 What is the overall classification of this malocclusion?
- 88.3 Give reasons for the Answer given in 88.2.



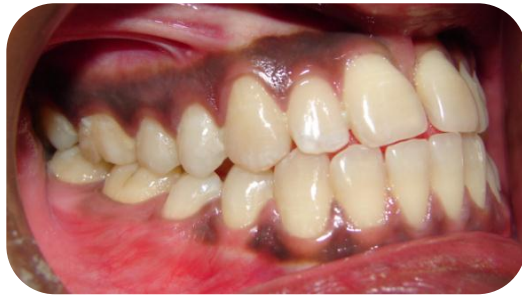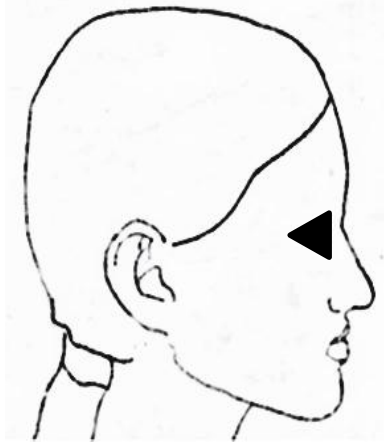## Case 89



89.1 What is the diagnosis of the malocclusion?

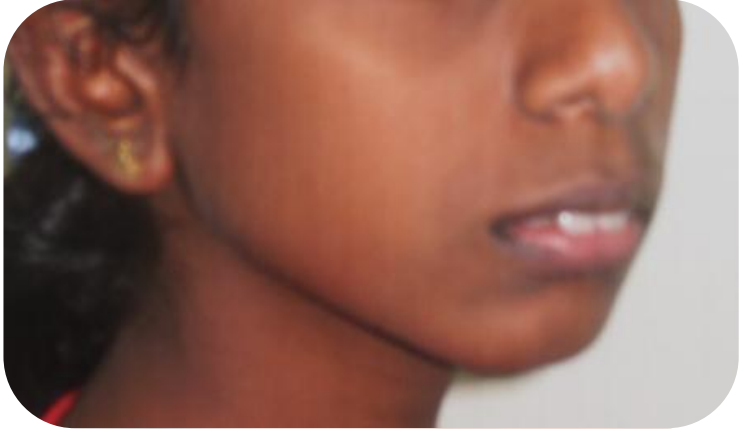89.2 What are the contributory factors for the development of this malocclusion?

## Case 90



- 90.1 Determine the antero-posterior discrepancy of skeletal bases by observing the facial profile.
- 90.2 What is the diagnosis of this malocclusion?
- 90.3 Give explanation for the presence of edge to edge Incisor Relationship.

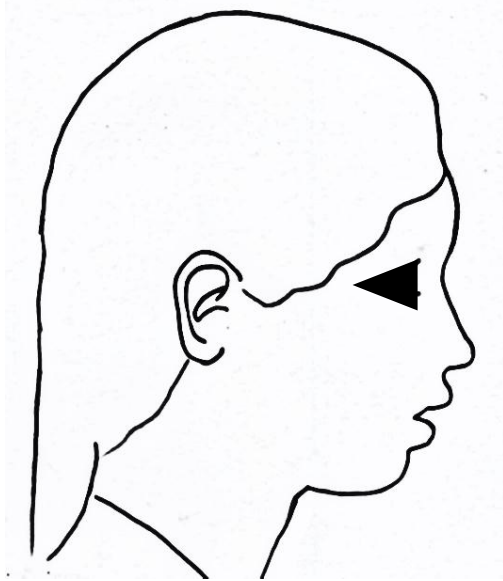
## Case 91



This 14 year old girl complained of inability to close the lips together.

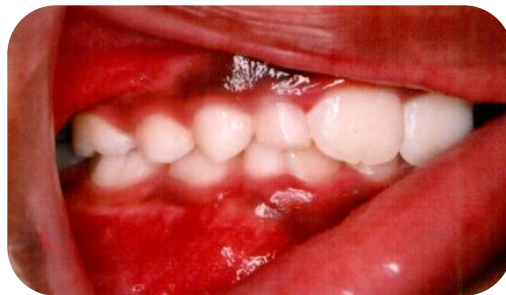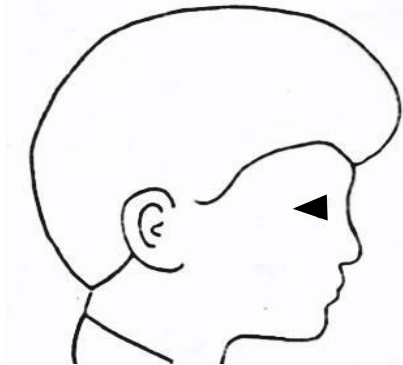
- 91.1 What is the relationship between the upper and lower lips?
- 91.2 Describe the presentation of the lower lip line.
- 91.3 Why is it necessary to prioritize Orthodontic treatment in patients presenting with above abnormality?

## Case 92



- 92.1 Determine the antero-posterior skeletal discrepancy between maxillary and mandibular basal bones by observing the facial profile.
- 92.2 What additional information would you need to make a conclusion?
- 92.3 How would you improve the facial profile of this patient?

## Case 93

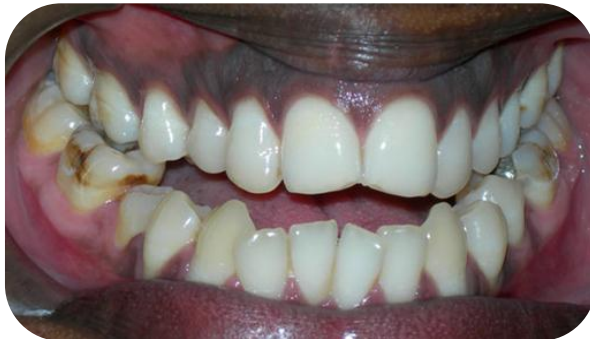
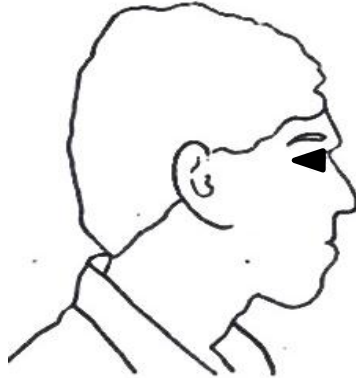
A 10 year old child presented for correction of her malocclusion.

93.1 What are the contributory factors for the development of the malocclusion?

93.2 Outline the treatment plan.

## Case 94



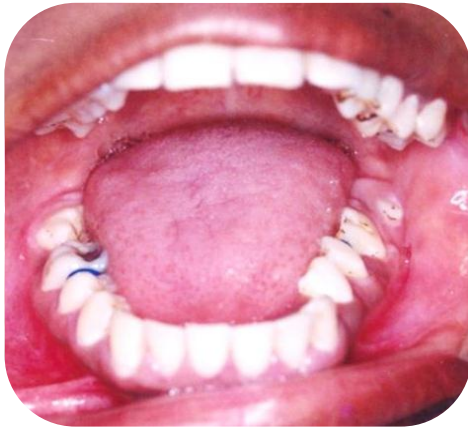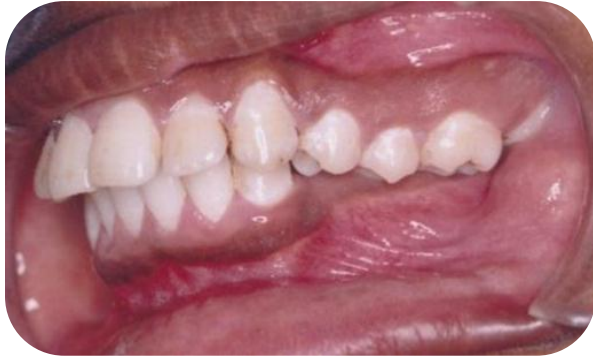Observe facial profile and occlusion of this patient.

94.1 State the skeletal discrepancies that you can detect from this profile.

94.2 What are the occlusal features that would reflect the skeletal discrepancy of this patient?

94.3 What is the best treatment modality for correction of this malocclusion?

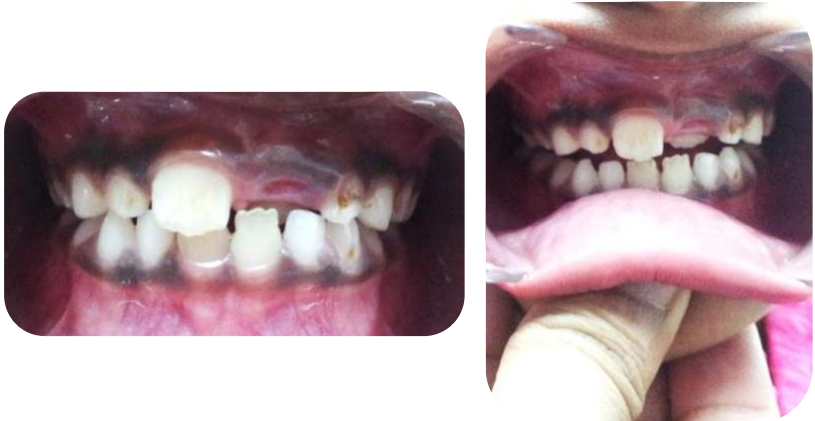## Case 95



95.1 What are the abnormalities seen in the left buccal occlusion?

95.2 How do you prevent the establishment of this kind of severe malocclusion?

## Case 96



These photographs were taken during Orthodontic examination of a patient presented with an incisor cross bite.

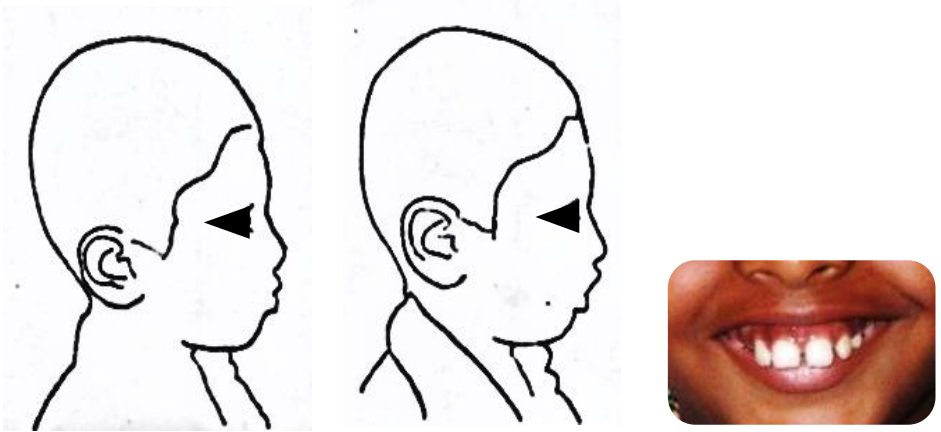
96.1 State the clinical feature that is being elicited.

96.2 What is the clinical significance of the finding mentioned in 96.1?

96.3 List the causes that may give rise to this phenomenon.



## Case 97



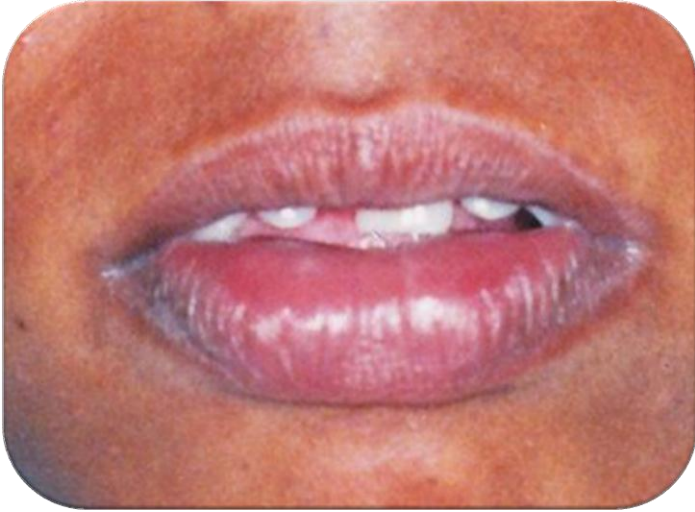These two profile views from the same patient were observed by a clinician when he presented for Orthodontic treatment. As the patient entered the clinic he was keeping the lips together and did not show significantly convex facial profile.

During extra oral examination it was observed that the patient had grossly incompetent lips and convex facial profile. Intra orally, he had Class II division 1 malocclusion.

97.1 Explain why the clinician observed this difference in facial profile.

97.2 What is the clinical significance of the finding?

## Case 98



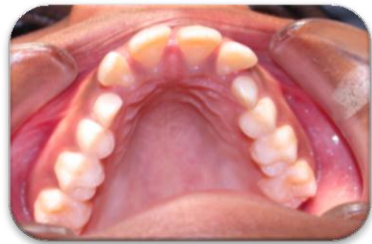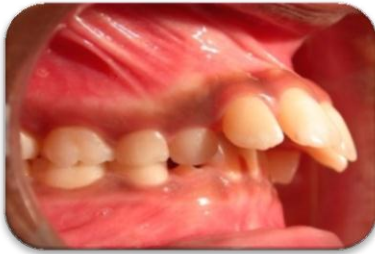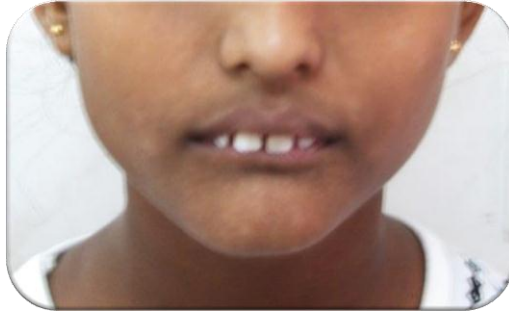A 14 year old boy presented with a complaint of inability to keep the lips together.

98.1 How do you describe,

- a. the relationship of the upper and lower lips?
- b. the lower lip line?
- c. contour of the lower lip?

98.2 What is the effect of the form of the lower lip on lower incisors in this patient?

## Case 99

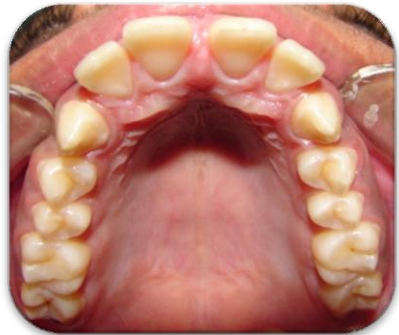
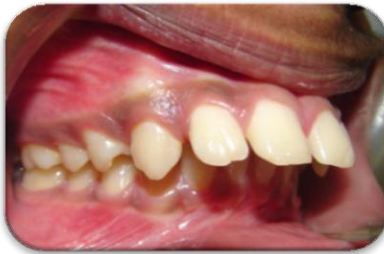
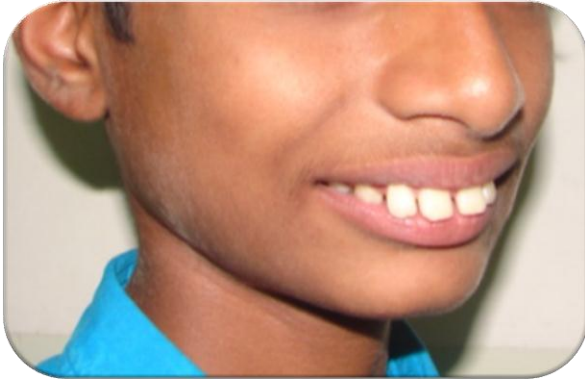A 11 year old child presented with a Class II division I malocclusion.

99.1 What are the irregularities seen in the upper arch?

99.2 Explain how this type of malocclusion develops.

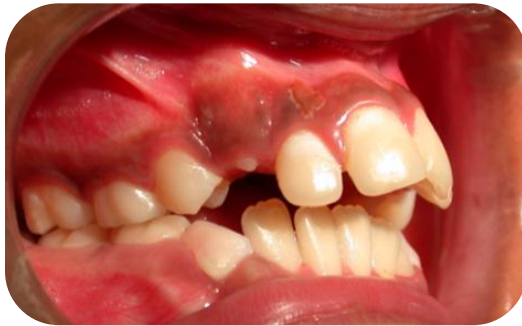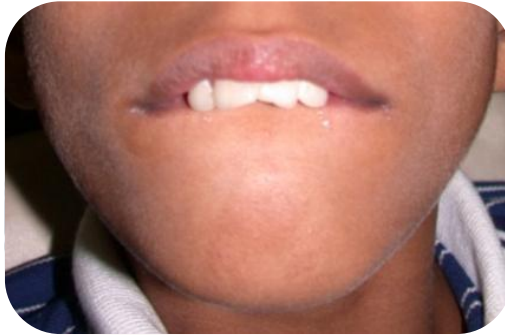## Case 100



This patient presented with Class II division 1 malocclusion with proclination of upper incisors.

Explain how this malocclusion is developed.

## Case 101

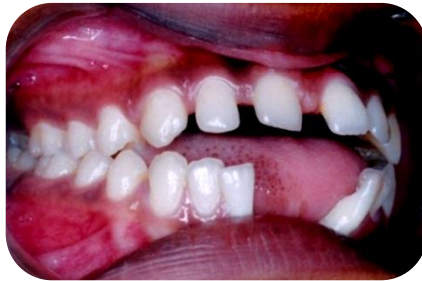
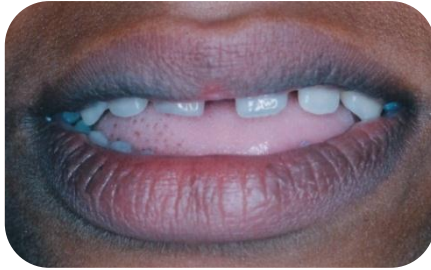
This child has been continuing the habit of lip sucking.

101.1 What are the obvious effects of this habit on developing occlusion?

101.2 List the steps in the management of this patient.

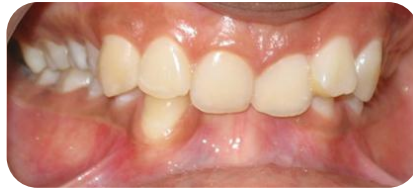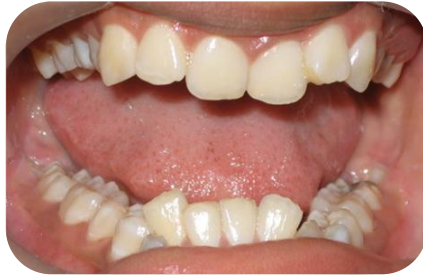## Case 102



A 16 year old girl presented with a complaint of inability to bite with front teeth.

- 102.1 What are the abnormalities that you observe in this occlusion?
- 102.2 What is the possible cause of these problems?
- 102.3 State the prognosis of orthodontic treatment.

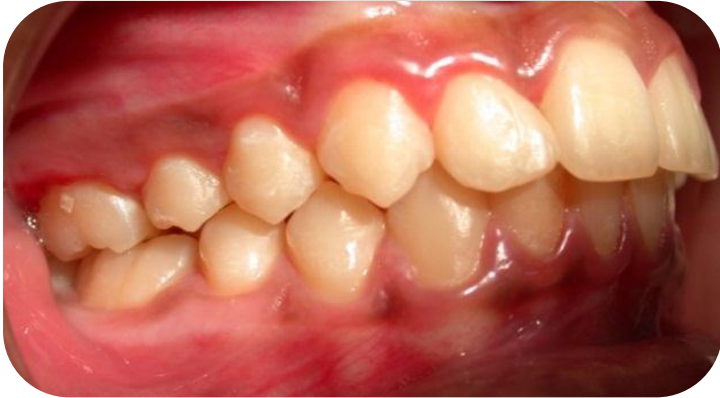## Case 103



Observe labial segments of this malocclusion.

- 103.1 Describe the inclination of upper and lower incisors.
- 103.2 Identify the abnormality in Incisor Relationship.
- 103.3 What could be the long term effect of the abnormality mentioned in 103.2?
- 103.4 What are the tooth movements that you would carry out to correct Incisor Relationship, if the patient has low vertical dimension and has passed the pubertal growth spurt?

## Case 104



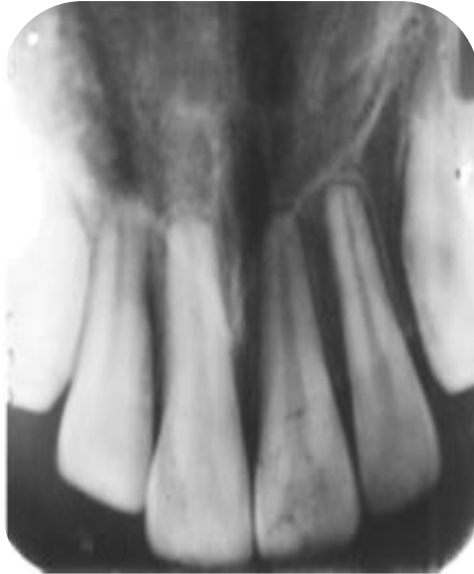
This patient request debanding of the fixed appliance before completion of the finishing phase of orthodontic treatment.

104.1 List the occlusal features achieved with treatment.

104.2 What are the other features that could have been corrected, if the patient agreed to complete the finishing phase of fixed appliance treatment?



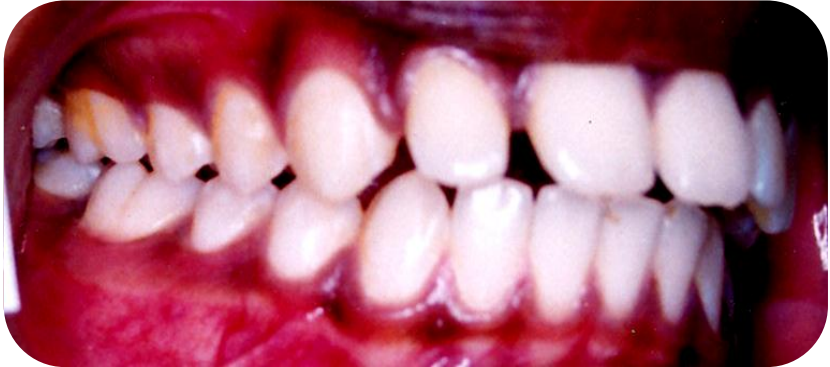## Case 105



This is a periapical radiograph of 15 year old patient who presented with a history of failed Orthodontic treatment.

- 105.1 Identify abnormalities seen in the radiograph.
- 105.2 What is the most likely cause of the abnormalities mentioned in 105. 1?
- 105.3 What are the complications that the clinician may experience if this patient is taken up for Orthodontic treatment?

## Case 106

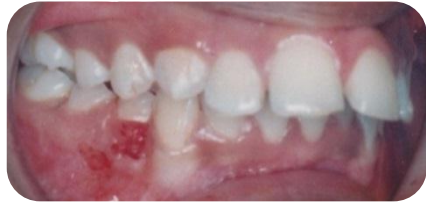
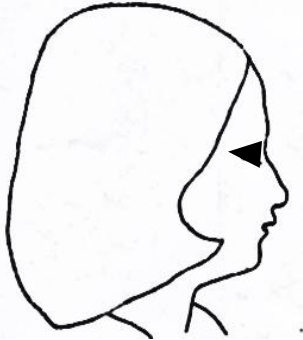
This is the occlusion of a 12 year old patient, who is undergoing orthodontic treatment using a removable appliance. Patient presented with a Class I malocclusion with upper incisor proclination and increased over bite on skeletal base Class I and average vertical dimension.

106.1 Comment on the over bite of this patient at present.

106.2 What is the mechanism that had been used to change the over bite?

## Case 107



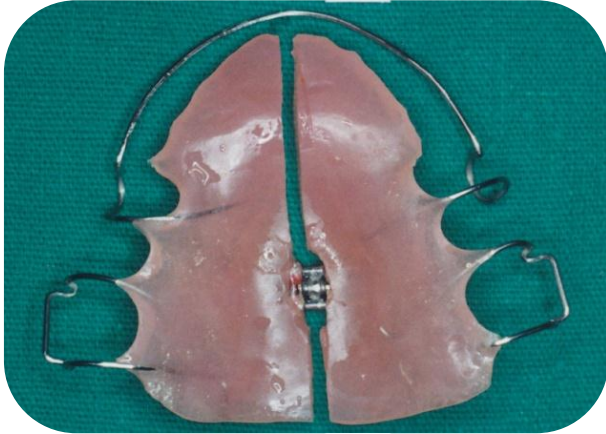A 12 year old girl requested to correct protrusion of upper teeth. Cephalometric tracing of the patient revealed the following,

- a. SNA –  $82^{\circ}$
- b. SNB-  $72^{\circ}$
- c. MMA-  $25^{\circ}$
- d. Upper incisor inclination  $120^{\circ}$
- e. Lower incisor inclination  $90^{\circ}$

107.1 What conclusions would you make regarding antero-posterior and vertical skeletal discrepancy of the patient by interpretation of cephalometric findings?

107.2 Justify the cephalometric interpretation for above findings, mentioned in 107.1.

## Case 108

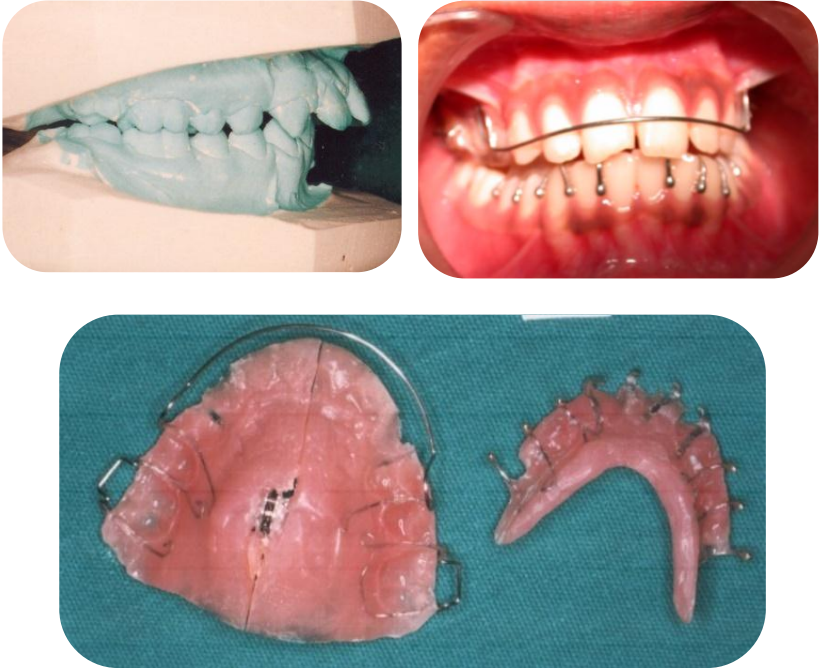


This appliance had been used in the first stage of Orthodontic treatment in the patient seen in question number 107.

108.1 What is the function of each component?

108.2 What would be the next step in the treatment plan?

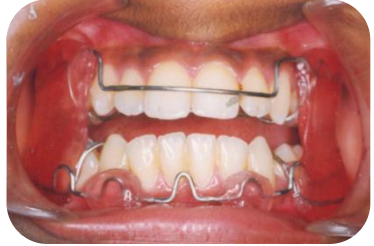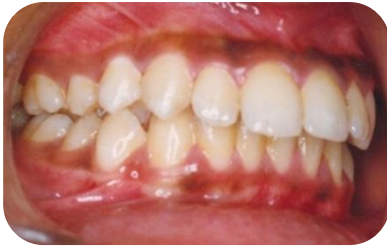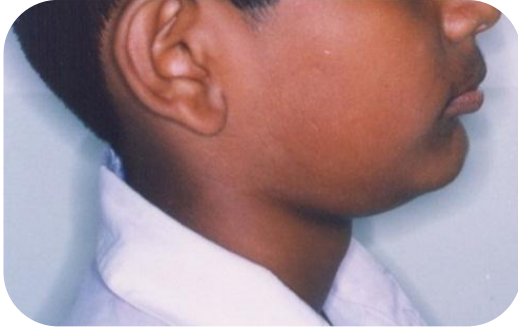## Case 109



These are records of a patient wearing a twin block functional appliance for correction of malocclusion.

- 109.1 Identify the components of the appliance.
- 109.2 List the typical clinical features of a patient suitable for correction of the malocclusion using a twin block appliance.

## Case 110



This boy is undergoing orthodontic treatment.

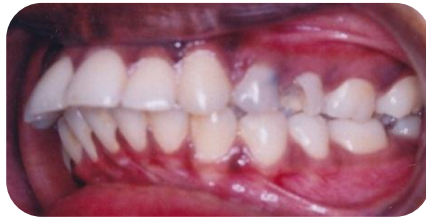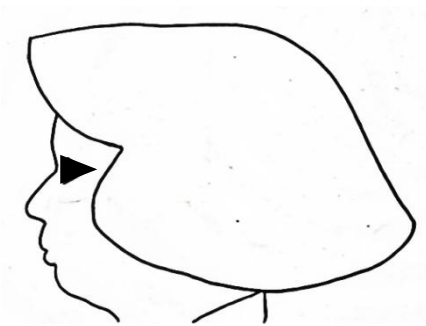
110.1 Identify the malocclusion that is observed.

110.2 Comment on the activity of the lower lip.

110.3 What is the appliance that has been fitted in the mouth?

110.4 What is the mode of action of this appliance?

## Case 111



This patient presented for orthodontic treatment with a complaint of receding chin. Examination of her occlusion did not reveal significant increase in over jet.

- 111.1 Explain why over jet is not increased significantly.
- 111.2 What is the best treatment option available for improvement of her facial profile if she has passed the pubertal growth spurt?





# Answers



## Answer 1

Pregnant mothers presenting with gingivitis and periodontitis have higher levels of chronic inflammatory mediators in their blood. These inflammatory mediators may contribute to the premature onset of contractions which leads to premature delivery and a low birth weight baby. Therefore, improvements of oral hygiene in pregnancy may help to reduce the incidence of possible complications.

Cariogenic bacteria are usually transmitted to the baby from an infected mother with dental decay. Therefore, it is important to treat all carious teeth before delivery. If not there is a risk of the baby getting infected with bacteria responsible for dental caries from mother (Vertical transmission of *streptococcus mutans* ).

## Answer 2

Advice about the following factors:

- a. **Teething:** if the child gets intermittent localized irritation in the area of erupting primary teeth, special care is needed (refer Answer 8 for further details)
- b. **Oral hygiene measures:** to start tooth-brushing soon after of eruption of the first primary tooth, by a parent twice daily, using a soft tooth brush of age-appropriate size and the correct amount of fluoridated toothpaste

- c. **Diet:** To avoid frequent night time bottle feeding ( milk with added sugar) and on demand breast-feeding in the night as these factors associated with dental caries
- d. **Fluoride:** to use the correct amount of fluoridated tooth paste (100 ppm) twice daily. Rice-sized amount of fluoridated tooth paste should be used for children under age three; a half pea-sized amount should be used for children age 3-6 and a pea size for children above 6 years. Optimal exposure to fluoride is important to all dentate infants and children
- e. **Injury prevention:** toddlers start to walk around 8 month onwards, therefore it is important to advice on prevention of orofacial trauma
- f. **Non-nutritive habits:** to discourage digit or pacifier sucking

Furthermore, educate regarding normal dental and oral development of the child.

### **Answer 3**

- 3.1
  - a. A Gingival cyst of newborn
  - b. An unerupted neonatal tooth
- 3.2 Treatment:
  - a. No intervention is indicated

- b. Keep under observation for eruption of the neonatal tooth  
(Refer Answer 7 for further details)

### **Answer 4**

- 4.1 Bilateral cleft lip and palate
- 4.2 a Problem of sucking as the baby cannot obtain anterior oral seal with lips
- b Inability to swallow as the cleft in the palate does not allow buildup of negative pressure inside the mouth required for swallowing

### **Answer 5**

- 5.1. Feeding plate
- 5.2. Feeding plate facilitates feeding by covering the cleft in the palate. As it facilitates swallowing, the baby will receive adequate nutrition enabling the growth of tissues before surgical repair of the lip is undertaken.

## **Answer 6**

- 6.1 Application of orthopaedic traction on pre-maxillary segment of the cleft
- 6.2 Restrain the independent growth of the pre-maxilla and approximate the lateral segments of the cleft to facilitate surgical repair of the lip

## **Answer 7**

- 7.1 Erupted neonatal teeth
- 7.2
  - a. Keep under observation - if the teeth are firm and symptomless
  - b. Extraction - if the teeth are,
    - I. continuously interfering with breast feeding
    - II. mobile (as there is a chance of aspiration)
    - III. traumatizing soft tissues (tongue)- even after smoothing the incisal edges of the neonatal teeth

## **Answer 8**

- 8.1 Teething
- 8.2 Associated clinical features:

- a. Increased drooling, restlessness and lack of sleep due to discomfort of gingivae
- b. Refusal of food due to soreness of the gingivae
- c. Putting fingers into the mouth
- d. Mild rash around the mouth due to skin irritation secondary to excessive drooling
- e. Rubbing the cheek or ear region due to referred pain during the eruption of the primary molars

Following clinical features are not usually associated with teething:

- I. High fever (especially over 101<sup>0</sup> F)
  - II. Diarrhea, runny nose and cough
  - III. Prolonged fussiness
  - IV. Generalized rashes
- 8.3
- a. If above mentioned clinical features are present,
    - I. reassure the parents
    - II. give analgesics to relieve the discomfort
    - III. give a chilled rings/ frozen damp cloth to bite
  - b. In the presence of unusual clinical features, seek medical advice early

## **Answer 9**

- 9.1 Finger brush which is made of rubber is not a suitable brush to clean baby's teeth. It does not remove plaque effectively and efficiently. Therefore, the usage of finger brush in babies is not recommended.
- 9.2
- a. From eruption of first tooth to completion of primary dentition use of a super soft junior brush is recommended
  - b. 3 - 6 years – Soft but a bit larger junior brush is recommended
  - c. 6 - 9 years (early mixed dentition) – Soft adult tooth brush modified by removing 2-3 rows of bristles is recommended
  - d. < 9 years – Soft adult tooth brush is recommended
- (Refer Answer two for further details on tooth paste)

## **Answer 10**

- 10.1 Eruption cyst in relation to 54
- 10.2
- a. If the patient is free of symptoms, keep under observation until spontaneous rupture of the cyst



- b. If child has pain or discomfort, incise the cyst with a number 11 blade

### **Answer 11**

- 11.1 Hyperkeratosis due to vigorous tooth brushing by over enthusiastic parents
- 11.2 Reassure the parents, advice to avoid vigorous tooth brushing and also to use a super soft junior tooth brush

### **Answer 12**

- 12.1 Reassure the parents. However, replantation of primary teeth is not indicated
- 12.2 Even though, the teeth were kept in an optimal transport medium and brought within one hour after the trauma, replantation is not indicated in primary teeth as it can damage the developing permanent teeth

## **Answer 13**

- 13.1 Lateral luxation with palatal displacement of 51
- 13.2 Extract 51 to prevent complications. Treat with antibiotics and analgesics. Arrange follow up appointment.

When there is lateral luxation of the primary tooth with more than 2 mm displacement, manual alignment could displace the developing permanent tooth bud. This may result in damage, dilacerations or hypoplasia of the developing permanent tooth.

## **Answer 14**

- 14.1 Early Childhood Caries (ECC)

Smooth surface caries occurs due to prolonged feeding during sleep. Carious lesions in this picture show features of arrested caries. If the child is already on preventive measures he should be motivated to continue the current practice.

- 14.2 Chronological hypoplasia
- 14.3 In Chronological Hypoplasia symmetrical horizontal hypoplastic bands should be present in the lower anterior teeth as well as in 62.

## Answer 15

15.1 Severe early childhood caries (S-ECC)

15.2 a. Introduction of preventive measures

b. Extraction of septic roots of 51, 52, 61, 62. Usually prescribing of antibiotics are not required

c. Treat other teeth as required

### **Preventive measures:**

- i. **Dietary modification** – S-ECC is due to prolong feeding (bottle milk with added sugar / breast feeding) during sleep. It is mandatory to discourage this habit. Fermentation of accumulated milk with sugar in between the upper lip and the tongue will produce weak acids. This weak acid will demineralize the upper anterior teeth where there is minimal salivary protection during sleep. The lower anterior teeth do not develop caries due to the protective action of saliva which accumulates in lower jaw due to gravitational effect.
- ii. **Plaque controlling methods** – Introduction of better brushing using fluoridated tooth paste (mechanical plaque controlling) is important. The amount of plaque that remain in the mouth is directly related to the amount of cariogenic bacteria in a high caries risk patient. Therefore, it is necessary to advice the parents to brush child's teeth twice daily, using a soft junior tooth brush

and a smear layer of fluoridated toothpaste (1000 ppm fluoride).

- iii. **Introduction of Fluoride** - For this child, topical fluorides such as fluoridated tooth paste (1000 ppm) and fluoride varnish should be introduced.
- iv. **Introduction of fissure sealants**- It is recommended to perform GIC fissure sealants in primary posterior teeth in high caries risk patient. With the eruption of first permanent molar teeth, resin based fissure sealants should be introduced.

## **Answer 16**

16.1 Down syndrome (A chromosomal disorder associated with an extra chromosome -Trisomy 21)

16.2 **General features:**

- a. Intellectual disability and delayed growth
- b. Vision and hearing problems
- c. Characteristic physical features: up slanted palpebral fissure, brachycephalic skull, prominent epicanthic skin folds, small low-set ears
- d. broad hands and feet, short fingers and single palma crease

### 16.3 **Oral and facial features:**

- a. Hypodontia, microdontia
- b. Hypoplasia of mid-facial region
- c. Macroglossia, fissured and protruding tongue
- d. Tongue thrust, bruxism, clenching, mouth breathing
- e. Delayed eruption of permanent teeth and malocclusion
- f. Early onset severe periodontal disease (most significant oral health problem)
- g. Low prevalence of dental caries (due to microdontia)

### 16.4 **Other potential disorders**

- a. Cardiac defects
- b. Epilepsy
- c. Atlanto-axial instability (fragility of cervical vertebrae/spinal cord)
- d. Increased risk of leukemia
- e. Hypothyroidism
- f. Compromised immune system
- g. Sleep apnea

## Answer 17

### 17.1 a. Clinical findings

- i. Fused 52 and 52
- ii. Carious 51 and 52 with periapical abscess.

### c. Radiological findings

51 and 52 shows features of fusion and obvious pulp exposure in 52 with periapical radiolucency. There is no radiological pulp exposure in relation to 51.

### 17.2 The fused teeth have two separated root canals.

- i. As 52 with obvious pulp exposure and periapical radiolucency, it should be treated with root canal treatment using  $\text{Ca(OH)}_2$  with iodoform in order to control the periapical lesion.
- ii. 51 with dentinal caries could be filled with glass ionomer cement as the tooth does not show a pulp exposure or periapical radiolucency in the radiograph.

These fused teeth should be maintained in the arch until their normal time of exfoliation. As there is minimal root resorption, it is necessary to maintain the tooth in the arch in order to restore the aesthetic and function. Therefore, extraction should be avoided.

Once the root filling is completed the crown restoration should be done with composite.

### **Answer 18**

18.1 Sturge–Weber syndrome is a neurological and skin disorder. (Encephalo Trigeminal Angiomatosis)  
It is a rare congenital, non-familial disorder of unknown etiology and is associated with,

- a. port-wine vascular malformation of the face
- b. glaucoma
- c. seizures
- d. mental retardation
- e. cerebral malformations and tumours

18.2 a. Introduction of meticulous preventive measures are mandatory to prevent dental extractions.

b. Even though, the extraction of many primary teeth are indicated in this patient and it should be managed in a tertiary care unit by an experienced oral and maxillofacial surgeon, with minimal trauma as there is a risk of excessive bleeding.

## **Answer 19**

- 19.1 Cross bite of labial segments in primary dentition
- 19.2 If the patient does not have displacement in path of closure of the mandible, the patient should have skeletal pattern Class III due to maxillary retrognathism.
- a. As there is relative maxillary retrognathism with reduced vertical dimension of the face, orthopaedic traction could be applied on the maxilla using a Reverse Pull Head Gear (Face Mask) with an intra-oral appliance of suitable design when the child is in early mixed dentition.
  - b. If residual skeletal discrepancy remains after facial growth is complete, patient may need surgical repositioning of the jaws.

## **Answer 20**

- a. Spacing in the labial segments as a result of growth
- b. Spacing due to occlusal attrition resulting in apparent spacing. This is due to wearing off of the wider occlusal part of the incisors leaving the narrower cervical part



- c. The relative incisor position has progressed towards an edge to edge relationship as a result of mandibular growth

(These changes prepare the jaws to accommodate the developing large teeth of the permanent dentition in correct alignment)

## **Answer 21**

21.1 Leis syndrome-Ectodermal Dysplasia which is associated with acanthosisnigricans

21.2 Leis syndrome is a rare genetic disorder of auto somal recessive transmission

Dermatological and dental characteristics are,

- a. hypodontia
- b. ectodermal dysplasia -hypotrichosis and hypohidrosis
- c. acanthosisnigricans
- d. palmoplantar hyperkeratosis
- e. nail dystrophy
- f. intellectual deficit
- g. skin pigmentation - perioral and periorbital hyperpigmentation
- h. vitiligo

- 21.3 Hypodontia need to be treated initially with removable partial dentures. Once the child completes the growth with implant retained fixed dentures.

### **Answer 22**

- 22.1 a. Dentinogenesis Imperfecta  
b. Amelogenesis Imperfecta  
c. Tetracycline discolouration
- 22.2 Dentinogenesis Imperfecta (DI) - Pathognomonic features of Dentinogenesis Imperfecta are partially or fully obliterated pulp chambers root canals and the opalescent discolouration of teeth.

### **Answer 23**

- 23.1 The perforated root of carious 51 which is mistakenly identified as a new tooth by the parent
- 23.2 Take a periapical radiograph of the upper central incisors
- 23.3 Extraction of root of 51 and observe eruption of permanent teeth. Space maintenance is not necessary as there is minimal space loss in relation to extracted primary incisors. The parents should be educated to compare with the eruption of 11 with 21.

There is a possibility of scar formation due to early extraction of 51, which can delay the eruption of 11.

## **Answer 24**

- 24.1 A periapical radiograph
- 24.2 74 - Pulp exposure with inter-radicular radiolucency  
75 - Pulp exposure with inter-radicular radiolucency  
36 - Healthy tooth  
37, 35, 34 - Developing inside the bone
- 24.3 As 74 and 75 show inter-radicular radiolucency with unresorbed roots, perform pulpectomy and fill the root canals of both teeth with  $\text{Ca}(\text{OH})_2$  with iodoform paste. The root canals of primary teeth should be filled with resorbable material which should be able to resorb with the eruption of the permanent tooth.

## **Answer 25**

- 25.1 Impaction of 46 against 85

25.2 Insertion of a brass separator or a separating module between 46 and 85 to disimpact 46. Furthermore over eruption of 16 would be observed with this condition

- 25.3
- a. Over eruption of 16
  - b. Loss of Leeway space in the lower right side
  - c. Impaction of 45

## **Answer 26**

26.1 Conical shaped supernumerary tooth

26.2 a. Investigate and exclude the presence of other unerupted supernumerary teeth in the premaxilla

b. Extraction of erupted conical supernumerary tooth

c. Observe eruption of permanent incisors after extraction of erupted supernumerary tooth. If un-erupted supernumerary teeth are present close to the roots of developing permanent incisors, defer surgical removal until root development of incisors is complete. The surgical manipulation of the region will damage Hertwig's root sheath of developing incisors affecting root completion

26.3 Developing incisal edges have mamelons. When they are exposed to masticatory forces, they gradually wear off with time

## **Answer 27**

- 27.1 Application of orthopaedic traction on the maxilla
- 27.2 Skeletal Pattern Class III due to relative retrusion of the maxilla in average to low angle cases
- 27.3 Force is transmitted to the circum-maxillary suture system using a Protraction Head Gear (face mask) via an orthodontic appliance fitted intra orally. As a result, growth and remodeling of the maxilla and forward translation of it is expected to correct Class III skeletal discrepancy

## **Answer 28**

- 28.1
  - a. Missing 41 and over-retained 81
  - b. Delayed eruption of 16 and 46
  - c. Submerged 85
  - d. Pulpotomy in 74
- 28.2
  - a. Extraction of root resorbed primary 71 and 81 in order to facilitate 31 to erupt with spontaneous alignment of lower labial segment depending on the developing malocclusion.
  - b. Surgical exposures of 16 and 46 to facilitate eruption
  - c. Surgical removal of 85 and place a distal shoe space maintainer which is fixed to 84 to guide eruption of 46 while maintaining space for developing 45

- d. Keep the pulpotomized 74 until eruption of 34. If it gets infected performed  $\text{Ca}(\text{OH})_2$  pulpectomy.

## **Answer 29**

29.1 A periapical radiograph

29.2 Periapical radiolucency in relation to mesial root of the 36 and extensive radiolucency in the crown. (On examination the tooth did not show occlusal caries - Occult caries)

29.3 Extraction of 36 as it is grossly carious with an extra-oral sinus

Eruption of 37 with spontaneous alignment could be anticipated as 37 shows initiation of calcification of bifurcation of the roots. Extraction of first molars in cases with missing premolars is contraindicated.

## **Answer 30**

30.1 Solitary Median Maxillary Central Incisor (SMMCI) Syndrome

30.2 Occur in 1:50,000 live births

30.3 a. Congenital nasal malformation

- I. Choanal atresia
  - II. Midnasal stenosis
  - III. Pyriform aperture stenosis
- b. May be associated with following anomalies
- I. Mild to severe intellectual disability
  - II. Congenital heart disease
  - III. Microcephaly
  - IV. Hypopituitarism
  - V. Hypotelorism
  - VI. Holoprosencephaly
  - VII. Cervical dermoid
  - VIII. Hypothyroidism
  - IX. Cleft lip and/or palate
  - X. Short stature

### **Answer 31**

31.1 Dental Panoramic Tomogram (DPT)

31.2 a. Over-retained 71 and 81 and missing 31 and 41

b. Median diastema in the upper arch

31.3 a. Over-retained 71 and 81

Over-retained 71 and 81 are due to missing 41 and 31. Need to keep primary lower incisors as long as possible with composite re-shaping of 71 and 81 to resemble permanent central incisors. This will prevent

over eruption of upper central incisors and also maintain the alveolar bone required for implant treatment in the future.

Later if the patient is concerned about the appearance, lower primary central incisors could be replaced with resin bonded cantilever bridges from 32 and 42.

- c. The median diastema in this child is physiological. Once the upper permanent canines erupt, the space will close spontaneously. The child should be kept under observation for further dental development and spontaneous space closure.

If contributory factors such as supernumeraries, high attachments are identified, remove them and correct malocclusion accordingly.

### **Answer 32**

- 32.1 Complicated crown fracture in 21 and uncomplicated crown fracture in 11
- 32.2 Pulpotomy had been performed using  $\text{Ca(OH)}_2$  / MTA (Mineral Trioxide Aggregate)
- 32.3 In the third radiograph roots of 11 and 21 show closed apices where as in the first radiograph both teeth show open apices. Vitality of the radicular pulp of 21 had been



maintained due to the pulpotomy and that tooth has obtained apexogenesis along with thickening of the root dentine.

### **Answer 33**

- 33.1
- a. Chromogenic bacterial stain, plaque and calculi in lower anterior teeth
  - b. Generalized marginal gingivitis
  - c. Gingival recession in 31
  - d. Repaired cleft lip (left) and alveolar cleft in relation to 22 region
  - e. Cross bite in relation to 21 and 41, 31 and cross bite in 63 and 73
- 33.2
- a. Improve oral hygiene
  - b. Interceptive orthodontics to correct the cross bite of 21 and 41, 31. Once the cross bite is corrected it will eliminate the continuous trauma on 31 from mandibular displacement resulting in spontaneous resolution of the gingival recession.
  - c. If it is necessary, surgical lip revision should be performed in the future. If there is a cleft in the

alveolus, it may need secondary bone graft prior to eruption of maxillary permanent canine.

### **Answer 34**

34.1 Upper standard occlusal radiograph

34.2 Clinical findings

- a. Over- retained carious 51
- b. Disto-labially rotated, distally displaced and partially erupted 11

Radiological findings

- a. Radicular cyst in relation to over-retained carious 51
  - b. Distally displaced 11
  - c. Developing crown of 13 overlapping on root of 12
- 34.3
- a. Extraction of 51 and surgical curettage of the radicular cyst is the initial step
  - b. Then, keep under observation for spontaneous alignment of 11 for 3 – 6 months

- c. If it fails to align spontaneously, correct the malaligned labial segment with an orthodontic appliance

### **Answer 35**

35.1 Treacher Collins Syndrome (Mandibulo Facial Dysostosis)

35.2 Characteristic features

- a. Cleft lip and palate
- b. Underdevelopment or absence of maxillary bones
- c. Malocclusion
- d. Lower jaw is often small and slanting
- e. Down-slanting eyes
- f. Notched lower eyelids
- g. The eyes have a tendency to dry out, which can lead to infection
- h. Underdeveloped or malformed ears
- i. Hearing defects
- j. Breathing and eating difficulties

Most children with Treacher Collins Syndrome show normal development and intelligence

35.3 Special dental care is needed in the following conditions

- b. Cleft lip and palate
- c. Malocclusion

## Answer 36

- 36.1
- a. Over retained 62
  - b. Radiolucent lesion in relation to crown of 22
  - c. Roots of permanent incisors are still developing
  - d. Dilaceration of root of 21 due to pressure from the pathological lesion on distal surface of the developing root
- 36.2. During formation of the root, pathological lesion applies pressure on Hertwig's root sheath causing displacement of the root resulting in dilaceration.
- 36.3. Establishment of the complete dilaceration within the root of the 21 and development of severe malocclusion in the permanent dentition.

## Answer 37

- 37.1 Chronological Hypoplasia
- 37.2 Through the history about childhood metabolic disturbances such as diarrhea, measles, otitis media
- 37.3 Hypoplastic defect should be corrected with composite restorations. Porcelain veneers or jacket crowns are indicated in severe cases

### **Answer 38**

- 38.1 Over retained 51  
As the patient is 8 year old, 51 is over retained  
Normal eruption time of 11 is around the age of 7-8 years
- 38.2 Upper standard occlusal radiograph/periapical radiograph of 11 and 21 region
- 38.3
- a. An unerupted supernumerary tooth
  - b. Ankylosed primary tooth
  - c. Dilacerated permanent tooth
- 38.4 The newly erupted tooth is a permanent tooth which is of normal shape and size. The small tooth present next to the newly erupted tooth is a primary tooth which has not exfoliated at the correct time. Generally the anterior primary teeth are smaller than permanent teeth and therefore, the problem lies in the retained primary tooth and not with newly erupted permanent tooth, as indicated by the parent.

### **Answer 39**

Extract over retained 51 and keep the patient under observation for eruption of 11. As the unerupted 11 still

shows an open apex, there is a possibility of spontaneous eruption of the tooth.

Review after 3-6 months for eruption of 11. If it fails to erupt proceed with surgical exposure and orthodontic traction to extrude it to the occlusal level.

### **Answer 40**

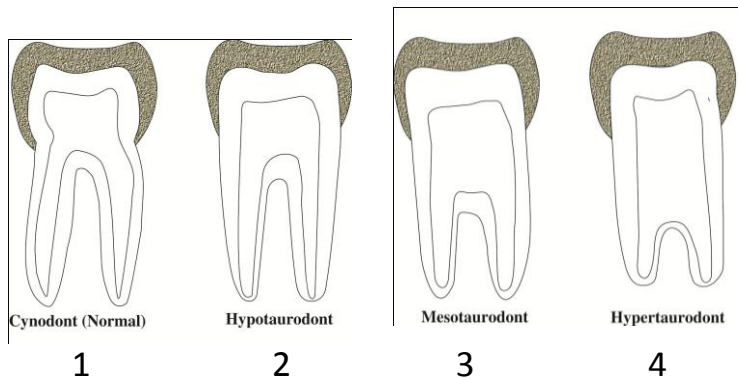
- 40.1 Lower incisor crowding. This is referred to as transient lower incisor crowding.
- 40.2 The crowding of lower incisors at this stage is quite natural and disappears with the further growth and development of the jaws, provided that all the other primary teeth or space is maintained till their normal time of exfoliation.
- 40.3
  - a. Take necessary precautions to prevent development of caries in primary teeth
  - b. Plan to maintain space for permanent teeth, If extraction of primary molars are unavoidable

## Answer 41

### 41.1 Dental Panoramic Tomogram (DPT)

41.2 Taurodontic first permanent molars – Taurodontism is a developmental anomaly of a tooth that lacks constriction at the level of the cement-enamel junction (CEJ) and is characterized by vertically elongated pulp chambers, apical displacement of the pulpal floor, and bifurcation or trifurcation of the roots of molar teeth. There are three presentations of Taurodontism based on severity, namely

1. Cynodont (Normal)
2. Hypotaurodont
3. Mesiotaurodont
4. Hypertaurodont



41.3 Endodontic treatment and extractions would be difficult due to large pulp chambers and slender roots

### **Answer 42**

42.1 Missing 21

42.2 Possible contributory factors:

- a. Supernumerary tooth
- b. Dilacerated 21
- c. Pathological lesions such as a cyst or a tumour
- d. Displaced / ectopic position of the tooth bud of 21
- e. Fibrous scar tissue due to early extraction of 61

### **Answer 43**

43.1 Unerupted, inverted and dilacerated supernumerary tooth

- 43.2
- a. Surgical removal of the supernumerary tooth to facilitate eruption of 21
  - b. Observe spontaneous eruption of impacted 21 (As 21 has an open apex)
  - c. If tooth fails to erupt spontaneously, apply orthodontic traction



- d. Later the child may need orthodontic treatment to complete alignment of incisors

### **Answer 44**

- 44.1 Two unerupted conical type supernumeraries on the right side. One is showing normal orientation and obstructing the eruption of 11. The other supernumerary tooth is inverted and does not cause any detectable effect on the developing dentition.
- 44.2 The prevalence of the supernumerary teeth in permanent dentition is 0.3- 3.5% and in the primary dentition it is 0.2-0.8%
- 44.3 Surgical removal of the supernumerary tooth which is obstructing eruption of 11. Bond an attachment for orthodontic traction on 11 and close the flap. Then observe spontaneous eruption of 11 for 3 months without applying traction. If not application of orthodontic traction on 11 is needed.

Inverted supernumerary tooth could be kept under observation as it does not cause any obvious interference to the developing dentition.

But it is mandatory to investigate it periodically to exclude the development of any pathology. e.g. cyst formation

## Answer 45

- 45.1
- a. Median diastema in the upper arch
  - b. Premature loss of 54 and distal drifting of upper incisors
  - c. Cross bite involving labial segments
  - d. Shift of the dental mid line
- 45.2
- a. Median diastema
    - I. Physiological
    - II. Presence of unerupted supernumerary teeth
    - III. Drift of the right upper anterior segment to the premature extraction site of 54.
  - b. Premature loss of 54 and distal drifting of upper incisors
    - I. Extraction due to caries, or other causes
    - II. Premature exfoliation of 54
  - c. Cross bite involving labial segments
    - I. Mild Class III Skeletal discrepancy
    - II. Presence of unerupted supernumerary teeth
  - d. Shift of the dental mid line due to premature loss of 54 and distal drifting of front teeth

## **Answer 46**

- 46.1
- a. Grossly breakdown of 73 with the root remaining
  - b. Premature loss of 74 and 75
  - c. Proclination of upper incisors with mild spacing
  - d. Distal angulation of 22
  - e. Over erupted 65
  - f. Incomplete reduced over bite
  - g. Slightly deviated dental center line
- 46.2 9 years
- 46.3 22 is distally angulated due to pressure applied by erupting 23

## **Answer 47**

- 47.1 8 to 9 years
- 47.2 21
- 47.3
- a. If the patient has Class I features and relatively large root of 22, upper anterior space could be closed by mesial movement of the 22 using fixed appliances
  - b. As the root of 22 is relatively large and 23 is favourable for eruption, prevent the mesial drift of 11 and guide the eruption of 23 in to the arch
  - c. Recontour 22 to resemble 21 and 23 to resemble 22

- d. Rotate 24 mesiopalatally, so that the palatal cusp of 24 is hidden in the front view of the occlusion in order to improve smile esthetics

### **Answer 48**

48.1 Clinical findings:

Over retained carious roots of 51, 52, 53, 62

Radiological findings:

Impacted 12

Dilacerated 11

- 48.2
  - a. Upper right central incisor shows features of dilaceration causing impaction of 12. This may be associated with childhood trauma to primary teeth
  - b. Distal transposition of 13 with 14
- 48.3
  - a. Extraction of over retained roots of 51, 52, 53 and 62
  - b. surgical removal of 11 (severe dilaceration) and bond a traction hook to 12. Observe spontaneous eruption for 3-6 months if not need to apply active traction

Management of dilacerated teeth:

Cone Beam computerized Tomogram (CBCT) is necessary to assess the severity of the dilaceration

- I. If it is mild to moderate dilaceration – Surgical opening and orthodontic traction is indicated.

- II. Severe dilacerations requires surgical removal of the tooth and orthodontic management of the space. Either space opening or closing depending on the malocclusion
- maintain space with a removable partial denture until the facial growth is complete and later plan for a resin bonded bridge
  - or maintain space and plan for an implant at a later stage, if adequate alveolar bone is remaining

### **Answer 49**

- 49.1 a. Germination of 12  
b. Fusion of 12 with a supernumerary tooth
- 49.2 Approximate diagnosis could be made using two periapical radiographs taken with different angulations. (Normal periapical radiograph and a mesially angulated periapical radiograph). The definitive diagnosis could be made using Cone Beam Computerized Tomogram (CBCT)
- 49.3 a. Development of caries along the fissures of double tooth.  
b. occlusalinterferences from the projected cusp /fused tooth
- 49.4 If it is a gemination –

- a. Gradual trimming of the additional cusp at one month intervals allowing irregular secondary dentine to form or
- b. One visit trimming of the cusp and elective endodontic treatment

If it is a fusion –

- a. careful surgical separation of the extra tooth and orthodontic alignment of 12.
- b. If not it may need extraction and management of the space (refer the Answer of 48.3 for further details).

## **Answer 50**

### 50.1 Oligodontia

This child presents with more than six missing permanent teeth, which is referred to as oligodontia.

Prevalence of congenitally missing teeth in permanent dentition excluding third molars is 0.15% - 16.2% and in primary dentition is 0.1% and 2.4%

- 50.2
  - a. Scanty hair
  - b. Dry skin
  - c. Heat intolerance

### 50.3 Ectodermal Dysplasia

It is a heterogeneous group of inherited disorders that are defined by primary defects in the development of two or more tissues derived from embryonic ectoderm. The

tissues primarily involved are the skin and its appendages (hair follicles, sweat glands, and sebaceous glands), nails and teeth.

## **Answer 51**

- 51.1 a. Confirm the diagnosis with a periapical radiograph and confirm the vitality
- b. Management of 11
- I. It exhibits an uncomplicated crown fracture which is very close to the pulp. Initial management of 11 is indirect pulp capping with setting Ca (OH)<sub>2</sub> and covering the fractured area with GIC. The crown repair could be completed with composite in two weeks.
  - II. If fractured piece of tooth is available it could be fixed with dual cured composite bonding agent or flowable composite over the Ca(OH)<sub>2</sub> dressing.
- c. Management of 21

This tooth exhibits an uncomplicated crown fracture involving enamel and dentine.

- i. In the absence of tenderness, tooth can be restored with composite on the same day.
- ii. In the presence of tenderness, cover the fractured tooth surface with GIC. Perform the definitive crown

restoration with composite in two weeks, once the signs and symptoms disappear.

- iii. If the fractured piece of tooth is available, it could be fixed using dual cured resin bonding material / flowable composite on the same day irrespective of presence or absence of tenderness.

## **Answer 52**

- 52.1
- a. Over retained 63 and 64
  - b. Multiple erupted supernumerary teeth
  - c. An un-erupted 21
  - d. Labially displaced 22 and 23
  - e. Partially erupted 23, 24 and 34 due to over retained 63 and 64
- 52.2.
- a. Investigate pre-maxillary region with radiographs
  - b. Remove all retained primary teeth
  - c. Remove erupted supernumerary teeth
  - d. Surgically remove unerupted supernumerary teeth present in the pre-maxillary region after roots of 21 and 22 are completely calcified.
  - e. If 21 is present and if it has an open apex allow spontaneous eruption
  - f. If 21 fails to erupt spontaneously expose and apply orthodontic traction
  - g. Later correct residual malocclusion accordingly



### **Answer 53**

- 53.1 a. High attached upper labial frenum with wide median diastema  
b. Crowding and rotation of lateral incisors
- 53.2 a. Take a periapical radiograph of 11 and 21 region (The presence of inverted V shaped notch between central incisors in the periapical radiograph confirms the presence of fibrous attachment)  
b. Close the median diastema half way with bodily movement using fixed appliance  
c. Thereafter perform frenectomy and close the diastema immediately before scar tissue is formed. Complete alignment of arches  
d. Retain incisors with a permanent retainer

### **Answer 54**

- 54.1 a. Extrinsic discolouration of teeth due to deposits of chromogenic bacteria  
b. Uncomplicated crown fracture of 11
- 54.2 a. Remove extrinsic stains with scaling and polishing. It is mandatory to introduce proper brushing methods. Otherwise discolouration will reappear due to re-deposition of chromogenic bacteria on plaque.  
b. Restore the uncomplicated crown fracture of 11 with composite. Root canal treatment is necessary if the tooth is nonvital.

## Answer 55

- 55.1 Complicated crown fracture of 11 with immature apex (open apex)
- 55.2 a. Partial pulpotomy (Cvek Pulpotomy)
- b. Pulpotomy
- c. Radicular pulpotomy
- d. Pulpectomy (Apexification of 11 using  $\text{Ca(OH)}_2$  / MTA)

As 11 is with immature root, it is necessary to maintain the vitality of the radicular pulp to induce root formation (apexogenesis) and also to obtain a thicker layer of radicular dentine by inducing secondary dentine formation.

- 55.3 Type of the treatment depends on:
- a. the extent of the infection of the pulp
  - b. the vitality of the traumatized tooth
  - c. the amount of the pulp exposure
    - i. This tooth shows large pulp exposure and if the patient presented immediately after trauma partial pulpotomy (Cvek Pulpotomy) could be considered.
    - ii. If patient presents late with a large pulp exposure pulpotomy or radicular pulpotomy is

indicated. The rationale is to keep the healthy pulp and remove the inflamed pulp.

- iii. If the pulp is totally infected or non-vital perform pulpectomy. Obtain apical closure using  $\text{Ca(OH)}_2$  / MTA prior to root canal treatment with Gutta Percha.

### **Answer 56**

- 56.1 Over eruption of 24 which is biting on the gingivae of the lower arch.
- 56.2
  - a. Prevention of development of caries in primary dentition.
  - b. Restoration of caries with building up of normal anatomy of primary teeth, if patient presents after development of dental caries.
  - c. Maintenance of space if extraction of primary teeth are unavoidable.

### **Answer 57**

- 57.1 Macrodonia of 12 and 21
- 57.2 Approximately 1.1%
- 57.3
  - a. It is necessary to confirm radiologically that these teeth are not double teeth, such as fusion, germination or the jaw being relatively small, giving

the appearance of macrodontia (relative macrodontia).

- b. It is possible to strip mesial and distal surfaces gradually to approximate 12 and 11.

### **Answer 58**

- 58.1
  - a. Bilateral repaired clefts of the upper lip
  - b. Bilateral unrepaired clefts of the upper alveolus
  - c. Bilateral pits in the lower lip
  - d. Angular cheilitis
  - e. Perioral keratosis

- 58.2 Van der Woude Syndrome (VDWS)

It is a genetic disorder characterized by pits in the lower lip, cleft lip with or without cleft palate or cleft palate alone. Other features associated with VDWS are hypodontia, narrow high arched palate, congenital heart diseases, syndactyly of hands, ankyloglossia and adhesions between upper and lower gum pads.

### **Answer 59**

- 59.1
  - a. Shape of the lateral incisor is abnormal (peg lateral)
  - b. Disto-buccal rotation of 13
  - c. Increased overjet
  - d. Class II quarter ( $\frac{1}{4}$ ) unit canine relationship

- 59.2 Reshape 12 with composite to the normal shape before eruption of premolars and canines, in order to prevent mesial drift of them to Class II occlusion.
- 59.3 a. As the patient presented after establishment of malocclusion, remove the peg lateral  
b. Complete alignment of upper arch with a fixed appliance.

### **Answer 60**

- 60.1. a. Mesially transposed 13 with 12  
b. Over retained 53  
c. Mesially angulated 12
- 60.2. Reshape 12 with composite to restore the normal shape of the lateral incisor in the mixed dentition.
- 60.3. a. Extraction of over retained 53  
b. Distal movement of 12 to facilitate the eruption of 13 or extrude it into the arch  
c. Alignment of both arches with fixed appliances  
d. Reshape 12 and 13 to resemble 13 and 12 respectively

Reshape 13 by trimming the cusp tip and the sides of the crown, reduce the prominence of the cingulum of 13 and reshaping it with composite to resemble 12. Reshape 12 with composite to resemble 13.

### **Answer 61**

- 61.1 a. Amelogenesis Imperfecta (AI)  
b. Fluorosis
- 61.2 a. Positive family history with pedigree analysis  
b. Whether the patient had been brought up in a fluoride endemic area during childhood.

Since the clinical appearance of above mentioned conditions are similar, genetic analysis is the best method to confirm the diagnosis.

### **Answer 62**

- 62.1. a 13, 33 and 43 are distally angulated  
b. 23 is mesially angulated
- 62.2. a. Mesially angulated canine can be moved with tipping movement  
b. Distally angulated canines need up righting and bodily movement  
c. Vertical canines need bodily movement

### **Answer 63**

- 63.1. Molar Relationship is Class I and Canine Relationship is Class II  $\frac{1}{4}$  unit
- 63.2. Class II division I malocclusion
- 63.3. Facial Profile and Antero-posterior skeletal relationship (determined either clinically or cephalometrically)

### **Answer 64**

- 64.1. At present the patient is having a very mild lower incisor crowding. Slight distal inclination of 42 and 32 with contact displacement. But in future this mild incisor crowding may get worse leading to changes in the lower arch.
- 64.2. With further growth and development of the dentition and the face child may develop tertiary crowding. The definite cause of this is not yet understood. But possible causes are,
- a. continuing growth of the mandible till late age after complete maturation of the maxilla
  - b. growth rotation of the mandible leading to increase in lower incisor crowding.
  - c. facial maturation
  - d. anterior component of the occlusal force
  - e. development and eruption of lower third molars

### **Answer 65**

- 65.1
- a. Upper incisors are proclined.
  - b. Supplemental 12 is present
  - c. 15 is palatally displaced and crowded

- 65.2 As the lower arch is well aligned, proclination and crowding of upper arch is due to the presence of supplemental 12.
- a. Decide the method for gaining space for correction of malocclusion. When malocclusion is caused by the presence of supplemental teeth, the space for correction of malocclusion is gained by extraction of one of them. Choice of extraction depends on the morphology of the supplemental tooth and the position of it in the line of the arch. Usually supplemental lateral incisor has a deep cingulum pit which has poor long term prognosis. If both are normal, the tooth which is most displaced from the line of the arch is selected for extraction.
  - b. Select the type of tooth movement and appliance needed. Correction of malocclusion needs root paralleling to close the space after alignment of teeth using a fixed appliance.

### **Answer 66**

- 66.1 Disclosing of plaque
- 66.2 Two tone plaque disclosing agent
- 66.3 To make the plaque visible. Plaque is colourless. Disclosing agents stain plaque in different colours making it visible. The agent used in above patient discloses



plaque in two colours, recent plaque in pink and old plaque in blue.

- 66.4
- a. Erythrosine – disclose plaque in red
  - b. Toluidine blue – disclose plaque in blue.
  - c. Fluorescein dye – disclose plaque only, expensive and need a special light to show stained plaque
  - d. Two tone dye – disclose old plaque in blue and new plaque in red or pink
- These products are available in the form of tablets and solutions

### **Answer 67**

- 67.1
- a. Aggressive periodontitis
  - b. Leukemia
- 67.2
- a. Investigate the mouth with radiographs. Look for the bone loss in relation to teeth specially in relation to molar teeth and incisors (aggressive periodontitis)
  - b. Look for the other features such as weight loss, fatigue, fever, night sweats, loss of appetite. Specially should check full blood count and blood picture to exclude leukemia.
- 67.3
- a. Aggressive periodontitis
    - i. scaling of the total mouth,
    - ii. Root surface debridement of deep pocket (based on the examination findings)
    - iii. Antibiotic

(Amoxicillin 250 mg and Metronidazol 200 mg 8 hourly for two weeks / doxycycline 100 mg 12 hourly for two weeks)

- iv. Follow up
- b. Leukemia  
If it is diagnosed as leukemia urgent referral to a hematologist or oncologist is mandatory

### **Answer 68**

- 68.1
  - a. Unrepaired crown fracture of 21.
  - b. Space loss in relation to missing 11 and 12 resulting in shift of upper midline towards the right side
- 68.2
  - a. Restore 21 with composite with or without root canal treatment depending on the pulp status (There is an increased possibility of 21 becoming non vital as broken tooth has not been restored immediately after trauma. Patent dentinal tubules that were exposed to the oral cavity may allow bacteria to travel towards the pulp chamber resulting in the death of the pulp.
  - b. Manage the malocclusion with orthodontic treatment to correct the center line and open up the lost space for prosthesis of 12 and 11.

### **Answer 69**

- 69.1
  - a. Root filled 21,
  - b. Root fracture of 11 and displaced apical 1/3<sup>rd</sup> of the fractured root

- c. Radiolucency in relation to broken root of 11
- 69.2 As 11 is non-vital, root canal treatment is indicated. Assuming 11 has an open apex;  $\text{Ca(OH)}_2$  or MTA apexification procedure should be introduced at the broken end of the coronal fragment, leaving apical 1/3<sup>rd</sup> as it is. If apical 1/3<sup>rd</sup> of the root is infected surgical removal is indicated.

### **Answer 70**

- 70.1 a. i. Unerupted 21.  
ii. Space available for 21 is reduced with mesial drift of 11. (Upper midline is shifted to left with mesial drift of 11).  
b. Partially erupted and proclined 22.  
c. Disto-buccally rotated 23.
- 70.2 a. Presence of unerupted supernumerary teeth in relation to 21  
b. Dilaceration of 21
- 70.3 a. Investigate 21 and 22 regions with radiographs.  
b. If 21 is normal, delayed eruption may be caused by un-erupted supernumerary teeth, expose, remove any un-erupted supernumeraries, bond an orthodontic attachment, apply traction on 21 and align the upper arch (21 may not have eruption potential at this age.)

- c. i. If 21 is dilacerated and the dilaceration is with poor prognosis for orthodontic traction and alignment, remove 21.
- ii. Open up space for 21 with fixed appliance and replace 21 with a prosthesis.

## **Answer 71**

71.1 Naso palatine duct cyst

71.2 Naso-palatine duct cyst is a developmental cyst. As the cyst develops, it occupies the space available for developing root of the 11. Therefore, Hertwig's root sheath get displaced laterally. Completion of the root and the calcification of it progresses with development of the dilaceration within the root.

71.3 Move 11 towards the midline with bodily movement using a fixed appliance.

71.4 11 is displaced distally without the shift of the dental center line. Width of diastema is more than 3 mm. Therefore, at the same time mesial movement of 11 should be prevented to close the diastema. It is necessary to move 21 mesially with bodily movement.

Fixed appliances are indicated for both requirements.

## **Answer 72**

- 72.1 a. Buccally displaced and crowded 23.  
b. Palatally displaced and crowded 22 which is in cross bite with 33.  
c. Shift of the upper dental center line.
- 72.2 Either premature extraction or carious break down of 63 and 64 resulting in loss of Leeway space and shift of upper dental center line to the left side.

## **Answer 73**

- 73.1 a. 11 is larger than 21  
b. 11 is disto-labially rotated and barrel shaped  
c. 12 is disto-palatally rotated  
d. 11 is overlapped with 12  
e. Slight space distal to 12  
f. Deep over bite  
g. 43 and 33 distally angulated
- 73.2. Fixed appliance
- 73.3 Correction of malocclusion needs multiple tooth movements which can be performed only with fixed appliances

## **Answer 74**

- 74.1 a Extrinsic stains (chromogenic bacterial stain)  
b Dilaceration of crown of 11
- 74.2 a Chromogenic bacterial stain will give unacceptable aesthetics

- b Dilacerated tooth will interfere with the occlusion and unaesthetic
- 74.3 a Scaling and polishing to remove the chromogenic bacterial stains.
- b i. Gradual trimming and re-contouring of the crown of 11 with composite.
- ii. If pulp exposure is unavoidable, elective endodontics is indicated.

### **Answer 75**

- 75.1 13-15 years
- 75.2 a. Erupted teeth -  
17,16,15,14,13,12,11,21,22,24,25,27,37,36,35,34,33,  
32, 31, 41,42,43,44,45,46,47
- b. Developing teeth - 28, 38, 48
- c. Impacted teeth - 23
- d. Pulp exposed teeth: 46 with periapical infection
- e. Missing tooth 26 –  
Mesially angulated 27 indicate the early loss of 26
- f. Over retained root - 63
- h. Abnormal 35 Possibility of partially erupted or lingually tilted 35 with hypo-plastic or carious lesion
- 75.3 a. Canine (23) is not in a favourable position for surgical exposure and traction. Extract 63 and surgical removal of 23. Space management with a removable partial denture or resin bonded bridge.

- b. Endodontic treatment of pulp exposed 46 with Gutta Percha and crown restoration with composite and observe spontaneous resolution of periapical infection. Once the periapical lesion is healed final restoration with porcelain fused metal (PFM) crown could be done.
- c. Partially erupted or lingually tilted 35 with hypoplastic or carious crown-regain the space of 35 orthodontically and restore the crown depending on the clinical presentation.

### **Answer 76**

76.1 Dens invaginatus of 45.

76.2 As 45 is non-vital with periapical radiolucency, it requires endodontic treatment.

Since the tooth shows an open apex, it is necessary to obtain apexification either with  $\text{Ca}(\text{OH})_2$  or MTA prior to Gutta Percha root canal filling

### **Answer 77**

77.1 a. Moderate to severe crowding of upper incisors.

b. Palatally displaced 12 and 22.

77.2 14 and 24

- 77.3 As 14 is grossly carious long term prognosis is poor. Alignment of the palatally displaced 12 and 22 requires, gaining of space by extraction of two premolars. In addition, extraction of both premolars indicated to maintain symmetry.

### **Answer 78**

- 78.1 Class I malocclusion with proclination of upper central incisors.
- 78.2 a. Slightly low lower lip line and slightly everted lower lip which has no control on inclination of upper central incisors allowing them to procline.  
b. Mesio-distal width of the 11 and 21 is also increased making them to erupt into a wider arc.

### **Answer 79**

- 79.1 Eruption of tuberculate supernumerary teeth in the upper labial segment.  
a. Preventing eruption of 21  
b. Resulting in labial and distal displacement of 11
- 79.2 a. Radiographic investigation of the upper labial segment  
b. Removal of extra teeth and retained teeth  
c. Observation of eruption and spontaneous alignment of 21



- d. if 21 is not erupting spontaneously surgical exposure and application of Orthodontic traction on 21.
  - e. Correction of the residual malocclusion with a fixed appliance
- 79.3.
- a. Tuberculate supernumerary teeth usually develop in pairs palatal to developing central incisors. Usually they prevent eruption of both central incisors. In this case 11 is erupted and displaced to the right side to 12 region Both tuberculate supernumerary teeth are erupted, instead of 21. Once supernumeraries are extracted, 21 should erupt if it has eruption potential. If not, it could be exposed and orthodontic traction could be applied.
  - b. Residual malocclusion needs correction with fixed appliances as multiple tooth movements are required.

### **Answer 80**

- 80.1
- a Surgical scar in the upper lip
  - b Wide alar base on the left side of the nose
- 80.2
- a Hypoplastic 21
  - b Missing 22
  - c Mesially angulated 23

## Answer 81

- 81.1 Severe Fluorosis
- 81.2 a. The patient is from fluoride endemic area in Wayamba province.  
b. Teeth shows typical mottled appearance
- 81.3 Mild fluorosis– The white opaque areas in the enamel of the teeth without enamel pitting.  
Moderate fluorosis -All enamel surfaces of the teeth are affected and surfaces subject to attrition. Brown stain is frequently a disfiguring feature.  
Severe fluorosis–All enamel surfaces are affected and hypoplasia is so marked that the general form of the tooth may be affected. The major diagnostic sign of this stage is discrete or confluent pitting. Brown stains are widespread and teeth often present with a corroded-like appearance.

## Answer 82

- 82.1 Upper arch – all permanent teeth from 17 to 27 and developing 18 and 28.  
Lower Arch - all permanent teeth are present except 34, 35 and 44.  
Over-retained 75 with a stainless steel crown.  
Developing 38 and 48 are present
- 82.2 Above 15 years

## Answer 83

- 83.1 a. Clinical Picture:
- I. Discoloured 11 and 21
  - II. Infraoccluded 11
- b. Radiologically:
- I. Severe root resorption of replanted 11 (with ankylosis)
  - II. Cervical root fracture of 21 with mesial displacement of the crown fragment
- 83.2 a Extraction of 11 (de-coronization is not indicated as there is hardly any root remaining)
- b Extraction of crown fragment of 21, leaving the root fragment of tooth in order to maintain the alveolar bone height.
- c Replace the crown of 11 and 21 either with a removable partial denture or cantilever bridges from 12 and 22

## Answer 84

- 84.1 Lower right second premolar shows features of hypoplasia. As other adjoining teeth do not show features of hypoplasia, of it does not represent chronological hypoplasia. This tooth seems to be a Turner's tooth which has occurred due to recurrent apical infections of 85.

- 84.2 Lower right second premolar (45) shows a deep dentinal carious cavity with near pulp exposure and 46 shows large radio opaque restoration.
- 84.3 As the first step all carious dentine should be removed carefully without touching the floor of the cavity. Floor should be cleaned with an excavator and look for the pulp exposure.
- i If there is no pulp exposure indirect pulp capping is indicated.
  - ii If it shows pulp exposure direct pulp capping is indicated.
  - iii If pulp gives features of irreversible pulpitis, pulpectomy is needed. In order to confirm the nature of the apex another periapical radiograph is needed.  
If it shows an open apex, apexification should be obtained with  $\text{Ca(OH)}_2$  / MTA followed by Gutta Percha root canal filling and if it shows closed apex direct Gutta Percha root filling is indicated.

### **Answer 85**

- 85.1 Swelling due to traumatic lip biting following local anaesthesia for bilateral dental extractions.  
Inferior alveolar nerve block affects the sensation of the lower lip. If the child bites the anaesthetized lower lip, it can cause trauma and subsequent inflammatory reaction. This is a possible complication of inadequate post-

operative instructions given regarding local anaesthesia or not following the instructions.

- 85.2 Reassure the patient and parents. Prescribe analgesics and antibiotics. Review the patient in three days to observe whether the swelling is subsiding.

### **Answer 86**

- 86.1 Asymmetry of the face with the chin deviated to the left side
- 86.2 Condylar hyperplasia of the mandible on the right side.
- 86.3 Scanning of the mandibular condyles with radioactive isotopes to detect active growth spots.
- 86.4 a. A hybrid type of functional appliance could be used to prevent further deterioration of the occlusion during pubertal growth spurt.
- b. Orthognathic surgery to correct the residual malocclusion and the facial deformity, after facial growth is complete.

### **Answer 87**

- 87.1 a antero-posterior relationship is Skeletal Class 1 (Skeletal pattern Class I)
- b Vertical dimension is average
- 87.2 Distal angulation of 42, 41, 31, and 32

(fanning of the lower incisors)

- 87.3 13 is missing (un-erupted) allowing mesial drift of 16 (When maxillary first molar drifts mesially, it rotates around its palatal root moving mesiobuccal cusp palatally)

### **Answer 88**

- 88.1 a Incisor Relationship is Class III  
b Canine Relationship is approximately Class II quarter unit  
c Molar Relationship is Class I
- 88.2 Class I Bimaxillary proclination
- 88.3 Patient has convex facial profile due to poor soft tissue pattern. Lower lip is everted. Tone of the muscles of the everted lower lip is not sufficient to oppose the effect of the tongue at rest. As a result, lower incisors are proclined causing Class III Incisor Relationship. Upper incisors are also proclined as the lower lip has no adequate control on inclination of the upper incisors.

### **Answer 89**

- 89.1 Class III malocclusion with upper severe and lower mild crowding on skeletal base Class III
- 89.2
- a Class III antero-posterior skeletal discrepancy of skeletal bases
  - b Transverse discrepancy of skeletal bases.
  - c Tooth arch size disproportion

### **Answer 90**

- 90.1 Mild skeletal Class III
- 90.2 Class III on skeletal base Class III partially compensated by dento alveolar changes
- 90.3 Patient is having mild Class III skeletal pattern. It has been masked by change of inclination of upper and lower incisors.  
(compensatory proclination of upper incisors and compensatory retroclination of lower incisors)

### **Answer 91**

- 91.1 Incompetent lips
- 91.2 Lower lip line is normal but acting behind the upper central incisors

- 91.3 As the upper central incisors are prominent, they are more prone to trauma. Therefore, priority for orthodontic treatment should be given over other malocclusions.

## **Answer 92**

- 92.1 Skeletal Pattern Class II
- 92.2 Whether patient's facial profile improves when the mandible is postured forward to Class I Canine Relationship

Skeletal Pattern Class II could be due to the discrepancy between maxillary and mandibular basal bones or discrepancy of each basal bone in relation to the cranium. In this patient, maxilla is normally related to the cranium and the mandible is retrognathic.

- 92.3 a If the patient is in growing stage, growth modification technique using functional appliance will improve the facial profile
- b If patient presents after completion of facial growth, orthognathic surgery to advance the mandible will improve the facial profile.



### **Answer 93**

- 93.1
- a Mild Class II antero-posterior skeletal discrepancy.
  - b Reduced lower facial height. (Low Angle)
  - c High lower lip line and vertical lower lip contour.

Interaction of these skeletal discrepancies in the two planes of space with soft tissues (lips) causes retroclination of upper incisors resulting in Class II division 2 Incisor Relationship.

- 93.2
- a If canines are developing high up in relation to the roots of 21 and 22, correct upper incisor inclination and the relationship in mixed dentition, either with a removable appliance or a sectional fixed appliance (2 x 4 appliance)
  - b Retain upper incisors with a permanent retainer.
  - c Observe whether continuing forward growth of the mandible worsen the malocclusion further. If malocclusion worsen, patient may need either camouflage of skeletal discrepancy or orthognathic surgery to improve facial aesthetics.

### **Answer 94**

- 94.1. a. Skeletal Pattern Class III (antero-posterior discrepancy between maxillary and mandibular basal bones).
- b. Increased vertical relationship than normal ( High angle )
- 94.2 a. Negative over jet – anterior-posterior skeletal discrepancy
- b. Anterior open bite – vertical skeletal discrepancy
- c. Bilateral buccal cross bites – transverse skeletal discrepancy
- 94.3 Orthognathic surgery

### **Answer 95**

- 95.1 a. Lingually inclined 34, 35 and 36.
- b. Buccally inclined 24, 25, 26 and 27
- c. Scissors Bite of 24, 25, 26, 27 and 34,35,36
- 95.2 Monitor the development of buccal occlusion to prevent establishment of scissors bite of 26 and 36 in mixed dentition. If detected after scissors bite is established, early correction of it to prevent worsening of occlusion.

## **Answer 96**

- 96.1. Premature contact between upper and lower left central incisors and forward displacement of path of closure of the mandible.
- 96.2 At present 31 does not show evidence of occlusal trauma due to displacement of path of closure of the mandible, as 21 is still erupting. If abnormal path of closure is not corrected early, it will damage the tissues even leading to the loss of 31.
- 96.3. a. Retained primary incisor  
b. Deviated path of eruption of 21  
c. Presence of supernumerary tooth  
d. Crowding  
e. Mild Class III skeletal relationship

## **Answer 97**

- 97.1. This difference is due to deviation of the path of closure of the mandible. If the patient is concerned about facial appearance, he maintains a habitual rest position of the mandible to mask the effects of the malocclusion. For the clinical examination when patient is asked to swallow and bite on the posterior teeth in order to determine the arch relationship, patient moves the mandible backward and upward directly from the habitual rest position to the centric occlusion. This is referred to as the deviation of

path of closure of the mandible. This movement could be observed in the chin.

- 97.2 a. If the clinical examination in orthodontics is carried out in the habitual rest position of the mandible, all findings will be incorrect and may not show severity of the malocclusion
- b. Further, in these patients functional appliances may not work as the patient has got used to the habitual rest position of the mandible

### **Answer 98**

- 98.1 a. incompetent lips
- b. low lower lip line. Just below the incisal edges of upper incisors
- c. everted lower lip
- 98.2. Muscle tone of the everted lower lip is not adequate to withstand the muscle tone of the tongue at rest. Therefore, lower incisors could be proclined.

### **Answer 99**

- 99.1 a. Proclination and spacing of upper incisors
- b. Narrowing of the upper arch in the canine premolar region.

99.2 The patient has Class II antero-posterior skeletal discrepancy and slightly reduced vertical dimension. Interaction of these two discrepancies with soft tissues results in the lower lip acting behind the upper incisors. This lip activity causes upper incisor proclination and spacing.

When a patient is unable to obtain anterior oral seal with upper and lower lips, which is necessary for swallowing, the tongue adapts to obtain anterior oral seal. In Class II division 1 cases, tongue moves forward to reach the lower lip to obtain anterior oral seal. If the patient continues with tooth apart swallowing pattern, the tongue is lowered down during swallowing. The effect of the buccinators contraction is not opposed by the tongue. This will result in narrowing of the upper buccal segments.

### **Answer 100**

Moderately prognathic maxilla, with combination of reduced vertical dimension of the face causes the lower lip to trap behind the upper incisors during activity. Therefore, upper incisors become proclined and spaced. As the patient cannot obtain anterior oral seal with upper and lower lips due to malocclusion, he learns an adaptive swallowing pattern by moving the tongue forward to reach the lower lip. If he continues with teeth together swallowing pattern, the tongue is not lowered down

during swallowing. Forces of the contracting buccinator muscles are balanced by the forces of the tongue. Therefore, this type of adaptive swallowing does not cause narrowing of the upper arch in canine and premolar region.

### **Answer 101**

- 101.1 a Retroclination and crowding of the lower incisors.  
b Proclination and spacing of the upper incisors.  
c Increased over jet.  
d Reduced and incomplete overbite.  
e Class II anterior- posterior arch relationship.
- 101.2 a Advise to stop lip sucking and observe spontaneous alignment of incisors.  
b Reassess the malocclusion and correct the residual malocclusion accordingly.

### **Answer 102**

- 102.1 a. Proclination of lower incisors  
b. Proclination and spacing of upper incisors  
c. Anterior open bite extending from 43 to 33  
d A large part of the tongue lying between upper and lower anterior teeth  
e. Reversed Curve of Spee.
- 102.2 Endogenous tongue thrust
- 102.3 Prognosis of orthodontic treatment is poor

### **Answer 103**

- 103.1. a 12, 11, 21 are retroclined.  
b 22 is proclined.  
c 42, 41, 31 and 32 are retroclined.
- 103.2 Class II division 2 Incisor Relationship with over bite increased more than 100% cover of lower incisors.
- 103.3 a Deep over bite may damage the labial gingivae of the lower incisors.  
b Occlusal ware of labial surface of the lower incisors
- 103.4 a True intrusion of incisors to correct deep over bite.  
b Root torque to correct the inclination of incisors and Incisor Relationship.

### **Answer 104**

- 104.1 a Normal over jet  
b Normal over bite  
c Correct angulation of teeth except angulation of 12.  
d Correct inter dental contacts  
e. Class I Incisor Relationship  
f. Class I Canine Relationship  
g. Andrew's Class I Molar Relationship
- 104.2 a Correct angulation of 12.  
b Maximum inter cuspatation of right buccal occlusion.

### **Answer105**

- 105.1 Resorption of roots of 12, 11, 21 and 22
- 105.2 Heavy force applied on upper incisors during previous orthodontic treatment
- 105.3 As all upper incisors show evidence of damage to the roots, further orthodontic treatment may worsen the damage even resulting in pulp death of incisors

### **Answer 106**

- 106.1 Overbite is reduced and incomplete. Occlusal plane (Curve of Spee) of the lower arch is rather flat.
- 106.2 Over bite may have been reduced by relative intrusion of the lower incisors using a removable appliance carrying a flat anterior bite plane.

### **Answer 107**

- 107.1
  - a Class II skeletal pattern with retrognathic mandible
  - b Low vertical dimension but within the average range
- 107.2
  - a  $SNA^0$  value is normal which denotes that maxillary basal bone is normally related to the cranium



- b  $SNB^0$  value is below normal range which denotes that mandibular basal bone is relatively retrognathic in relation to cranium
- c  $ANB^0$  value is  $10^0$  indicating skeletal Class II discrepancy
- d  $MMA^0$  is within the normal range, but relatively close to the lower value (normal value is  $27 \pm 5^0$ )
- e Upper incisors are proclined and lower incisors are normally inclined.

### **Answer 108**

- 108.1
- a Adams Clasps for retention of the appliance
  - b Mid line expansion screw for compensatory expansion of the upper arch as a preparation for the correction of malocclusion with a functional appliance
  - c Flat Anterior Bite Plane to reduce over bite with relative intrusion of the lower incisors
  - d. U loop labial bow for correction upper incisor proclination
- 108.2 Use of activator type functional appliance to correct antero-posterior skeletal discrepancy

## **Answer 109**

- 109.1. a. Upper Block
- I. Adams Claps on 16 and 26
  - II. U loop labial bow
  - III. Midline expansion screw
  - IV. Bite Bocks on posterior teeth
- b. Lower Block
- I. Ball Clasps on incisors, canines and premolars
  - II. Bite Blocks on premolars and canines
- 109.2 a Class II antero-posterior skeletal relationship with relative retrognathism of the mandible (Facial profile improves when the lower jaw is postured forward into Class I Canine Relationship)
- b well aligned lower arch (Preferably spaced and retroclined lower incisors)
  - c well aligned upper arch
  - d Class II Molar, Canine and Incisor Relationship

## **Answer 110**

- 110.1 Class II division 1 malocclusion with retroclined lower incisors.
- 110.2 Hyperactive lower lip (Hyperactivity of mentalis muscle is causing retro-clination of the lower incisors.)

110.3 Frankel 2

110.4 Eliminate adverse muscle forces on the lower arch in order to facilitate the development of dental arches.

### **Answer 111**

111.1. Patient has Class II skeletal discrepancy due to relative retrusion of the mandible. This discrepancy has been masked by compensatory proclination of lower incisors. Therefore, the over jet and the incisor relationship do not reflect the severity of the discrepancy of skeletal bases in sagittal plane.

111.2. Surgical correction of skeletal discrepancy in sagittal plane with de compensation of proclination of lower incisors and surgical augmentation of the chin.